



## A RARE CASE OF GIANT SPIGELIAN HERNIA PRABHU E ELUMALAI

Department of General Surgery, MADURAI MEDICAL COLLEGE AND HOSPITAL

**Abstract :** Background - Spigelian hernia is an uncommon spontaneous lateral ventral hernia. It usually occurs below the arcuate line of Douglas. Incidence is 0.12 of all ventral hernias. Risk of strangulation is high and is around 20. It is very difficult to diagnose because of vague symptoms and usually requires radiological imaging when asymptomatic. Case study - We had a 55 year old female, with complaints of swelling pain in the left lower abdomen. It measures about 20x15cms in the left lateral border of rectus. Probable diagnosis of spigelian hernia was made. Abdominal x-rays didn't reveal any signs of intestinal obstruction. Ultrasonogram and CT confirmed the diagnosis of Spigelian hernia. So patient was taken up for surgery electively and open mesh repair was done. Postoperative period was uneventful and patient was discharged on 9th post-op day. Conclusion -Weakness presented in the linea semilunaris in Spigelian hernia may be caused either spontaneously or factors that increase the intra-abdominal pressure and this case is presented because of its rare occurrence and appropriate management .

**Keyword :** giant spigelian hernia, semi-lunar line

### Introduction:

Spigelian hernia is defined as protrusion of peritoneal sac with or without intra-abdominal organs through a congenital or acquired defect in semi-lunar line. The anatomic basis of spigelian hernia is supported by weakness in aponeurosis of transversus abdominis muscle from the lateral border of rectus sheath and semilunar line. It's a rare entity representing 0.5-2% of abdominal wall hernias. At the time of appearance 90% are asymptomatic. Between 10-20% occurs with strangulation, making diagnosis and treatment important. When the defect is <2cms simple closure is sufficient. When the defect is large, mesh repair is recommended. Risk of recurrence is 2%.

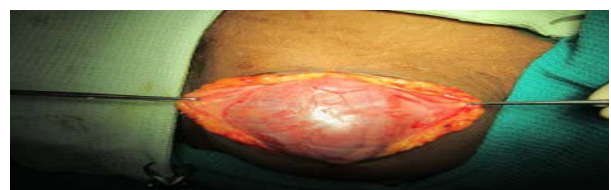
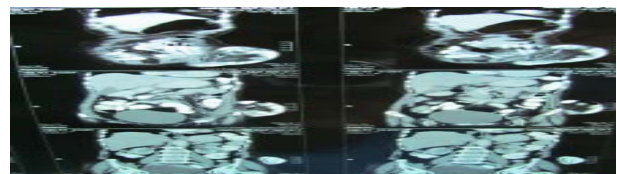
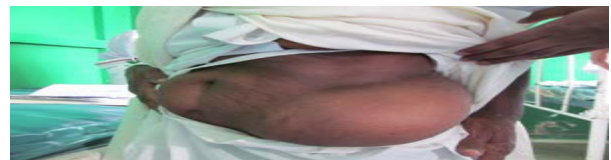
### Case report:

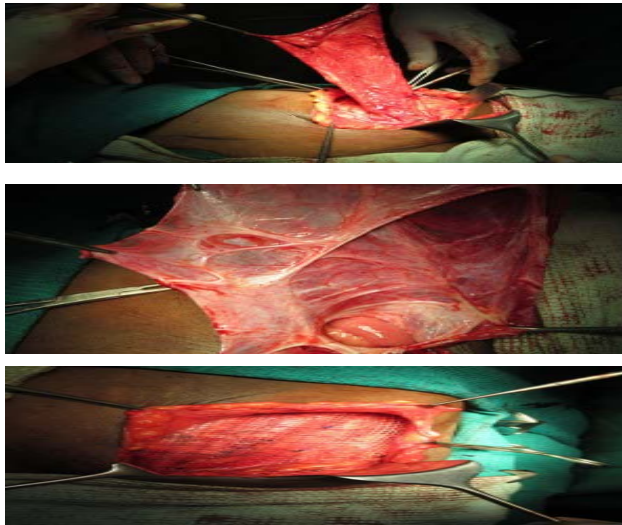
A 55 year old female presented to surgery dept with complaints of swelling in the left lower abdomen for the past 10 years and abdominal pain for the past 10 days with no other co-morbid conditions. On examination swelling of size 20x15cms in the left lateral border of rectus along the semilunar line.

An Initiative of The Tamil Nadu Dr. M.G.R. Medical University  
University Journal of Surgery and Surgical Specialities

Swelling was not reducible, cough impulse absent, no visible pulsations or peristalsis, bowel sounds present. Probable diagnosis of spigelian hernia was made. Abdominal x-ray does not show multiple air fluid levels. Ultra sonogram abdomen and CT confirmed the diagnosis of spigelian hernia. Patient was taken up for surgery under Epi-GA, transverse incision was made and abdomen opened in layers and the sac of size 15 cms identified. The sac opened with ileum as content, defect measured 6x5cms lateral to the rectus sheath. Excess sac removed and defect closed with interrupted sutures.

Then hernioplasty done using a polypropylene mesh. Complete hemostasis attained. A 12 Fr suction drain placed and wound closed in layers. Post-operative period uneventful and patient discharged on 9th post-operative day.





#### Discussion:

Spigelian line was first described by Belgian anatomist Adriaan Van Der Spiegel. Its the transition line between the muscle bundles and aponeurosis of transversus abdominis muscle. Spigelian hernia was first reported by Holloway in 1922. It remains to be considered a mystery because in majority of cases its cause is unknown. However some factors have been associated with its presentation which include copd, obesity, rapid weight loss, abdominal trauma, multiparity, laparoscopic procedures, BPH & cryptorchidism. In pediatric population it may be caused by undescended testis and consequent increase in intra-abdominal pressure. Mostly occurs in the spigelian hernia belt, the 6cms area of spigelian aponeurosis that lies cephalad to inter-spinal plane. M:F ratio is 1:1.8. More common in 4th to 6th decade of life. More common on right side. The concept of giant spigelian hernia has been defined according to the sac and defect size, Defect of size 4-10cms and hernial sac dimensions of 10-18cms (table 1). Lawler et al. were probably the first to use the term 'giant' spigelian hernia. Spigelian hernias should always be operated due to risk of strangulation. Patients with undiagnosed recurrent pain abdomen should be searched for this condition to avoid complications. It should also be differentiated from other conditions such as rectus sheath hematoma, parietal abscess, parietal lipoma, metastatic deposits. Laparoscopic TAPP and TEP is coming up with good results. In this case we have done a open mesh repair. Table 1. Reports that use the term "giant" in reference to spigelian hernia

Author	Country and year of publication	Size of defect (cm)	Size of the sac (cm)
Topal et al	Turkey, 2007	7 × 10	-
Lawler et al	U.S., 1966	4	10 × 10 × 18
Conzo et al	Italy, 2000	7	-
Ribeiro et al	Brazil, 2005	-	10x10
Gil-Galindo et al	Mexico, 2011	9x12	15x15

Conclusion: Although spigelian hernia is uncommon, it is important to know the rare condition for the appropriate management of spigelian hernia.

#### References

- Houlihan TJ. A review of spigelian hernias. *Am J Surg* 1976;131:734-735.
  - Montes IS, Deysine M. Spigelian and other uncommon hernia repairs. *Surg Clin North Am* 2003;83:1235-1253.
  - Broughton G 2nd, Alvarez JD. Repair of a spigelian hernia. *J Am Coll Surg* 1997;185:490-491.
  - Zaragoza C, Peiró F, Bebek H, Castaño S, García Aguado R, Vivó M, et al. Spigelian hernia: ambulatory surgical treatment. *Ambulatory Surg* 2001;9:127-129.
  - Mathonnet M, Mehinto D. Anterolateral hernias of the abdomen. *J Chir (Paris)* 2007;144:5S19-22.
  - Holloway JK. Spontaneous lateral ventral hernia. *Ann Surg* 1922;75:677-685.
- Author Country and year of publication
- Size of defect (cm) Size of the sac (cm)
- Topal et al Turkey, 2007 7 × 10 -
- Lawler et al U.S., 1966 4 10 × 10 × 18
- Conzo et al Italy, 2000 7 -
- Ribeiro et al Brazil, 2005 - 10x10
- Gil-Galindo et al Mexico, 2011 9x12 15x15
- Durham MM, Ricketts RR. Congenital spigelian hernias and cryptorchidism. *J Pediatr Surg* 2006;41:1814-1817.
  - Raveenthiran V. Congenital spigelian hernia with cryptorchidism: probably a new syndrome. *Hernia* 2005;9:378-380.
  - Rushfeldt C, Oltmanns G, Vonen B. Spigelian-cryptorchidism syndrome: a case report and discussion of the basic elements in a possibly new congenital syndrome. *Pediatr Surg Int* 2010;26:939-942.
  - Truong T, Costantino TG. Images in emergency medicine. Traumatic abdominal wall hernias. *Ann Emerg Med* 2008;52:182-186.
  - Belev N, Deenichin D, Angelov A. Case of severe thoracic and abdominal trauma with flail chest and traumatic spigelian hernia. *Khirurgiia (Sofia)* 1981;34:379-381.
  - Iuchtman M, Kessel B, Kirshon M. Trauma-related acute spigelian hernia in a child. *Pediatr Emerg Care* 1997;13:404-405.
  - Moreno-Egea A, Campillo-Soto A, Girela-Baena E, Torralba-Martínez JA, Corral de la Calle M, Aguayo-Albasini JL. Traumatic spigelian hernia. Elective extraperitoneal laparoscopic repair. *Cir Esp* 2006;79:61-63.
  - Topal E, Kaya E, Topal NB, Sahin I. Giant spigelian hernia due to abdominal wall injury: a case report. *Hernia* 2007;11:67-69.
  - Lawler MR Jr, Carlisle BB. Giant spigelian hernia. *Am J Surg* 1966;111:562-564.
  - Rossi E, Carbone M, Candela G, Brunese L, Salzano A. Giant spigelian hernia: assessment with computerized tomography and surgical correlations. Report of a case. *Radiol Med* 1999;97:196-197.
  - Conzo G, Giordano A, Candela G, Di Marzo M, Marone U, Santini L. Giant spigelian hernia associated with inguinal hernia. Repair with polypropylene prosthesis. *Minerva Chir* 2000;55:611-615.
  - Ribeiro EA, Cruz Junior RJ, Moreira SM. Intestinal obstruction induced by a giant incarcerated Spigelian hernia. Case report and review of the literature. *Sao Paulo Med J* 2005;123:148-150.
  - Prieto J, Ayloo S. Image of the month. Spigelian hernia. *Arch Surg* 2007;142:305-306.

20. Amodio F, Hierholzer J, Mansueto G, Lemke A, Smaltino F. Quiz case of the month. Latero-ventral hernia of the abdominal wall (spigelian hernia). Eur Radiol 2000;10:1839-1840.
21. Larson EE. Spigelian hernia. Am J Surg 1951;82:103-106.
22. Ignatius JA. Spigelian hernia. Am J Surg 1955;90:388-391.

