



Analytical Study of Impacted Foreign Bodies in Thoracic Surgery and Their Surgical Modalities

T Muthu Vijayan , A Kumaravel.

Assistant Professor, Department of Cardiothoracic Surgery.

Abstract

Introduction: Foreign bodies (FBs) in the thoracic cavity, its wall or other vital organs in the thorax are not uncommon. Their introduction in the thorax is by various methods. Especially inhalation and ingestion of FBs are common in young children and aged people.

Materials and Methods: Between August 2004 to April 2007, 20 patients had been operated for impacted FBs. All patients were admitted initially in E.N.T Department or Paediatric Department and subsequently referred to Cardiothoracic Surgery Department. All patients underwent routine screening by chest X-ray and computed tomography chest/magnetic resonance imaging whenever needed. The trial attempt of removal by esophagoscopy/bronchoscopy was done by other specialists.

Results: The obtained results are depicted in tabular form Tables 1-3 and Figure 1.

Conclusion: FBs in the aerodigestive tract get impacted due to the disparity in the size and lumen diameter. Commonly non-vegetable FBs tend to get impacted, for example, open safety pin, dollar, and coins fish bones, which needs active surgical intervention 85% are radio-opaque FBs and 15% are radiolucent.

Key words: Bronchus, Foreign body, Oesophagus, Surgical intervention
INTRODUCTION

Foreign bodies (FBs) in the thoracic cavity, its wall or other vital organs in the thorax are not uncommon. Their introduction in the thorax is by various methods. Especially inhalation and ingestion of FBs are common in young children and aged people. Traumatic introduction of FB are more common in the middle age group negligence to intervene immediately, and disparity in size of the FB to the passage

where it gets lodged leads to impaction and renders surgery the only option for relief and cure, for example, FB in aerodigestive tract. FB in heart, great vessels and lungs is an emergency to be managed as they embolize and complicate. FB in chest wall and pleural cavity demands immediate surgical attention to prevent complication like infection and subsequent disability.1-4

Month of Submission : 11-2016

Month of Peer Review : 12-2016

Month of acceptance: 12-2016

Month of publishing: 01-2017

Although FBs from the aerodigestive tract have been revolutionized by removal using rigid/flexion bronchoscopes/esophagoscopes. The mainstay in surgical when impaction of the FBs occur.5-8

In this study, the surgical technique and modalities for the management of various of FBs in thorax has been discussed. All cases were referred cases from other specialties such as E.N.T, pediatric surgery, and general surgery were the first line of management has failed.8-12

Aim of the Study

Analytical study of the types of impacted FBs that occurs in thoracic surgical practice and surgical modalities opted in the management of them in various parts of thorax.

Investigations

Radiological findings

X-ray examination of the patient must be performed and should include all the structures from the nasopharynx to the tuberosities of the ischia; otherwise, the FB maybe overlooked.

X-ray should be taken with the neck extended with anteroposterior and lateral views. Anteroposterior views in expiration and inspiration should be taken, although these views are sometimes difficult to obtain in very young children. A lateral chest X-ray completes the chest examination.

Screening may also help, but standard X-rays are usually sufficient (Gaffar *et al.*, 1982). Computerized tomographic studies may help to show an FB not seen with conventional studies (Berger *et al.*, 1980) isotope scans will demonstrate changes in ventilation and perfusion of lung tissues. These more sophisticated radiological techniques are rarely necessary in obvious cases of inhaled FBs. They should not be ordered if they delay the definitive endoscopic assessment of the patient.

A lateral view of the FB should always be taken. Not only may this reveal some FBs which might otherwise be missed but also on occasion, a child may have ingested two FBs, one smaller than the other which is tucked out of site on the anteroposterior neck/chest radiograph. Objects such as wood, aluminum, glass, plastics, meat and as indicated, dental plates may not be visible without the use of contrast solutions. One helpful sign on the lateral cervical soft tissue film is the presents of a prevertebral gas shadow above an impacted FB in the upper esophagus. This is not frequently overlooked by accident and emergency department staff who presumably are more intend on seeking out evidence of FB itself. Where the history is clear, it is probably not vice to carry out a barium swallow because endoscopy will be complicated by the obscuring presence of the barium.

MATERIALS AND METHODS

Between August 2004 to April 2007, 20 patients had been operated for impacted FBs. M: F - 12:8. Incidence was more common among young (0-30 years), though we had come across old patients also (70-75 years).

All patients were admitted initially in E.N.T Department or Paediatric Department and subsequently referred to cardiothoracic surgery department. All patients underwent routine screening by chest X-ray and computed tomography chest/magnetic resonance imaging whenever needed. Trial attempt of removal by esophagoscopy/bronchoscopy was done by other specialists.

Failure of the above technique landed the patient for surgical exploration by thoracic surgeons. The removal of radio-opaque FB's was done with on table X-ray guidance/c-arm. Removal of radiolucent FB's was done with on table reconfirmation of position with esophagoscopy/bronchoscopy.

RESULTS

The obtained results are depicted in tabular form Tables 1-3 and Figure 1.

DISCUSSION

FBs in the aero- digestive tract are more common in younger children and the old.

Boys are more frequently involved than girls in the ratio of 2:1.

Children have not developed a full posterior dentition and may have immature neuromuscular mechanisms for swallowing and airway protection.

Adults – neurologic dysfunction, dental trauma, and aspiration of larger than normal pieces of food, usually associated with alcohol consumption.

Unawareness about the seriousness of the problem a negligence leads to varied complication. For example, FB in the esophagus leads to inflammation and retropharyngeal abscess formation and subsequent septicemia.

Table 1: Sex ratio (n=20)

Males	Females
12	8

Table 2: Age group affected

Age in years	Sex	
	Males	Females
0-10	3	3
11-20	2	2
21-30	3	2
31-40	1	-
41-50	1	-
51-60	1	-
61-70	1	-
71-80	-	1
81-90	-	-

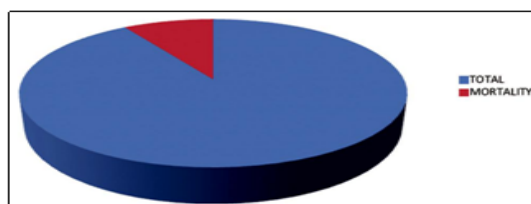


Figure 1: Complication of impacted foreign body. Total (91%), Mortality (9%)

Table 3: Types of foreign bodies

S. No.	Objects	No. of cases presented	Type of foreign bodies
1	Denture (esophagus)	4	Radio opaque
2	Safety pin-open (esophagus)	3	
	Closed	1	
3	Surgical 11 blade (pleural cavity)	1	
4	Bone piece (esophagus)	2	
5	Sewing needle (r.v chamber)	1	
6	Iron rod (chest wall/mediastinum/pleural cavity)	2	
	Metal cap of soft beverage bottle (esophagus)	1	
8	Coin (esophagus)	2	Radiolucent
9	Plastic nozzle of pen/bead (bronchus)	2	
10	Glass piece (pleural cavity)	1	

FB in the bronchus leads to atelectasis initially and later bronchiectasis changes in the lung which may need lobectomy

Septicemia was the most common mode of death in patients who, are submitted for surgical exploration of the impacted FB. Second, vascular invasion or erosion of the inflammatory process contributes to the collapse and death of the patient.

FB in the pleural cavity iatrogenic (5%) and traumatic (5%) were encountered in adult patients. Empyema with loculation was found in a case 11 blade in the pleural cavity. Prompt recovery was seen on surgical intervention.

FB in the myocardial chamber (5%) cardiopulmonary bypass to arrest the heart and retrieve the FB.

Three stages of symptoms- initial event of violent paroxysm of coughing, choking, and gagging possibly airway obstruction occurs immediately. Followed by asymptomatic interval due to reflex fatigue. The third stage is complications.

Child with recurrent asthma or croup should suspect with FB aspiration.

Diagnosis usually delayed more than 1 day in 50% of cases and more than a week in 15% of cases.

X-ray posteroanterior and lateral views are needed for the diagnosis.

Radiolucent FBs cannot be detected by X-rays. Initially, the object creates a bypass valve which still allows ingress and egress of air. At this stage, radiography results are normal.

As edema of the surrounding bronchial wall develops, a check valve is created. On inspiration, the bronchus dilates and permits ingress of air. However, on expiration, the bronchus constricts and contact of the edematous bronchus with the FB block the egress of air. Hence, inspiratory film will be normal but expiratory film will show hyperinflation of the affected lung with shifting of mediastinum to opposite side.

Enough edema develops to block ingress and egress of air; a stop valve is created. Obstructive atelectasis is seen radiologically.

Treatment of choice is reasonably prompt endoscopic removal under conditions of maximal safety and minimal trauma.

Two situations exist, acute emergency, and acute potential airway obstruction.

In acute situations, abdominal thrusts can be given, but it is not recommended for children less than 1 year.

If obstruction persists despite these efforts, cardiopulmonary resuscitation should be continue until skilled medical personal and appropriate equipment are available to secure the airway.

Acute potential airway obstruction cases rigid or flexible endoscopies can be used for retrieval of the FBs.

The overall morbidity (4%) and mortality (9%), in this study, are based on the awareness on the side of the patient to seek medical attention at the earliest and timely active surgical intervention.

Surgical principles.

Cervical esophagus - oblique incision along the left sternomastoid muscle and exploration of esophagus done in visceral space of neck.

Thoracic esophagus - Right thoracotomy.

Bronchial FB - Prone position of patient and left/right posterolateral thoracotomy as indicated.

Myocardium - Cardio-pulmonary by pass instituted to arrest the heart and remove FB.

Others - Chest wall-local incision pleural cavity – right/ left anterolateral.

CONCLUSION

FBs in the aerodigestive tract get impacted due to the disparity in the size and lumen diameter.

Commonly non-vegetable FBs tend to get impacted, for example, open safety pin, dollar, and coins fish bones, which needs active surgical intervention 85% are radio-opaque FBs and 15% are radiolucent.

X-ray chest "C" arm, esophagoscopy and bronchoscopy

(flexible) are the mainstay of assessment, presurgically to plan an intervention.

Earlier reporting of patients with earliest intervention as discussed above, combined with meticulous post-operative care gave good results with low morbidity and minimal mortality.

REFERENCES

- Holinger LD. Management of sharp and penetrating foreign bodies of the upper aerodigestive tract. *Ann Otol Rhinol Laryngol* 1990;99:684-8.
- Biswas B, Datta R. Retained oesophageal foreign bodies - Report of three cases. *Indian J Otolaryngol Head Neck Surg* 1999;51 Suppl 1:15-8.
- Banerjee S. Concept of foreign body-its past and present. *Indian J Otolaryngol Head Neck Surg* 1999;51 Suppl 1:23-30.
- Brown TC, Clark CM. Inhaled foreign bodies in children. *Med J Aust* 1983;2:322-6.
- Murthy PS, Ingle VS, George E, Ramakrishna S, Shah FA. Sharp foreign bodies in the tracheobronchial tree. *Am J Otolaryngol* 2001;22:154-6.
- Banerjee A, Rao KS, Khanna SK, Narayanan PS, Gupta BK, Sekar JC, *et al.* Laryngo-tracheo-bronchial foreign bodies in children. *J Laryngol Otol* 1988;102:1029-32.
- Hassan AM, Ghosh P, Menon PS, Kaul HL, Mukhopadhyaya S. Changes in tracheobronchial angles as a function of age. *Indian J Otolaryngol Head Neck Surg* 1993;2:1-6.
- Cunanan OS. The flexible fiberoptic bronchoscope in foreign body removal. Experience in 300 cases. *Chest* 1978;73 5 Suppl:725-6.
- Nandi P, Ong GB. Foreign body in the oesophagus: Review of 2394 cases. *Br J Surg* 1978;65:5-9.
- Wilson RT, Dean PJ, Lewis M. Aorto-esophageal fistula due to a foreign body. *Gastrointest Endosc* 1987;33: 448-50.
- Baraka A, Bikhazi G. Oesophageal foreign bodies. *Br Med J* 1975;1:561-3.
- Sadan N, Raz A, Wolach B. Impact of community educational programmes on foreign body aspiration in Israel. *Eur J Pediatr* 1995;154:859-62

