



## MALIGNANT GIST OF STOMACH WITH SYNCHRONOUS GALL BLADDER ADENOCARCINOMA

SRINIVASAN

Department of General Surgery,  
STANLEY MEDICAL COLLEGE AND HOSPITAL

### Abstract :

The coexistence of GIST with either synchronous or metachronous gastrointestinal adenocarcinomas represents a phenomenon with increasing number of relative reports in the literature over the last 5 years. A 65 yr old female with dyspeptic symptoms for the past 6 months and a normal OGD was found to have a large heterodense exophytic lesion arising from the stomach in the CECT Abdomen which was suggestive of a GIST. On laparotomy, she was found to have a tumor arising from posterior wall of stomach infiltrating into the distal pancreas and an incidental Cholecysto duodenal fistula. A subtotal gastrectomy with a distal pancreatectomy, splenectomy and cholecystectomy was done with a Roux-en Y gastrojejunostomy. The Histopathological examination of the specimen revealed a high grade GIST of stomach, which was CD 117 Positive and an INFILTRATING ADENOCARCINOMA of the gall bladder. The Patient was started on adjuvant chemotherapy with 5-FU and subsequently she succumbed to the disease 3 months later. In any case of GIST, the surgeon should be alert to recognize a possible coexistent tumor with different histological origin and perform a thorough preoperative and intraoperative search. The correct diagnosis before and at the time of the surgical procedure is the cornerstone that secures the patients' best prognosis.

**Keyword :** GIST, Leiomyosarcoma, stomach, Gall bladder adenocarcinoma, synchronous

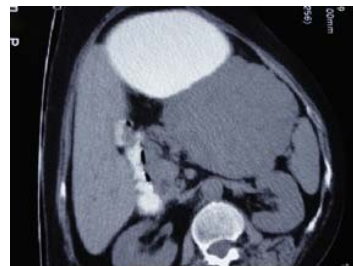### INTRODUCTION

The occurrence of synchronous gastrointestinal adenocarcinomas with GIST has been reported frequently over the past 5 years and we present an interesting case of synchronous gall bladder adenocarcinoma with a malignant GIST of stomach.

### CASE STUDY:

65-Year-old female presented with complaints of vague upper abdominal pain and bloating dyspepsia for 6 months. She had no h/o jaundice / hematemesis / melena and no h/o loss of weight or appetite. Her Bowel and bladder habits

were normal. She was a Known diabetic and hypertensive on treatment. She had no h/o surgeries in the past. On examination, her general condition was fair with a karnofsky performance status of 90%. She had no pallor / icterus / pedal edema. Her abdomen was soft with no palpable mass or organomegaly. Per rectal examination revealed no deposits. Routine investigations including CBC, RFT and LFT were within normal limits. Stool occult blood was negative. An upper GI endoscopy was done which was also normal. USG abdomen and pelvis revealed a large heteroechoic mass of size 11\*9 cm in the region of tail of pancreas - ?

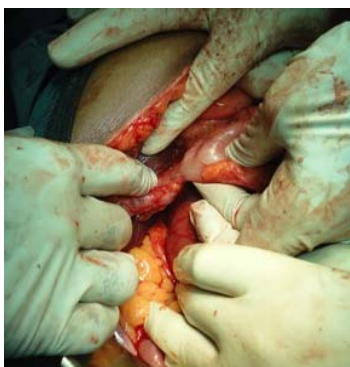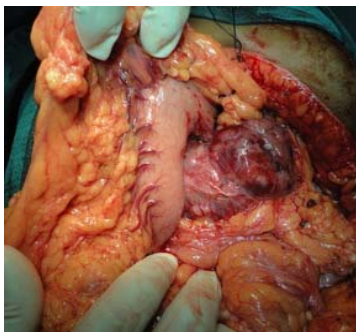


**Fig 1: CECT Abdomen showing a large exophytic lesion arising from the stomach**

Retroperitoneal mass for evaluation. A CECT Abdomen was done which revealed a large exophytic lesion arising from stomach - ?GIST (Fig 1).

The case was discussed in the Tumor board and a decision for an exploratory laparotomy and proceed was taken. Per operatively there was a tumor arising from posterior wall of stomach infiltrating into the distal pancreas extending upto splenic hilum (Fig 2). There was also an incidental Cholecysto duodenal fistula between Gall Bladder and the first part of duodenum (Fig 3). There was no stone / distal obstruction in CBD which was confirmed by an intraoperative cholangiogram. The Liver surface was normal. There was no ascites/ pelvic / peritoneal deposits. A subtotal gastrectomy including adequate margins

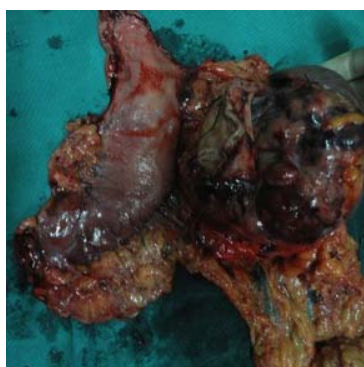for the tumour and including the fistula in first part of duodenum was done along with a distal pancreatectomy, splenectomy and cholecystectomy (Fig 4). A Roux-en Y gastrojejunostomy, jejunojejunostomy and Feeding jejunostomy were done.



**Fig 2: Tumour arising from the posterior wall of stomach infiltrating into the tail of pancreas**

**Fig 3: Cholecystoduodenal fistula between gall bladder and first part of duodenum**

**Fig 4: Specimen of subtotal gastrectomy with tumor, tail of pancreas and spleen**



The postoperative period was uneventful. The Histopathological examination of the specimen revealed the lesion from stomach to be a high-grade Malignant Gastrointestinal Stromal Tumour which was CD 117 – positive. The Gall bladder had an INFILTRATING ADENOCARCINOMA – MODERATELY DIFFERENTIATED. The patient was discussed in the tumor board again and it was decided to start adjuvant chemotherapy with 5-FU. Patient had completed

3 cycles of adjuvant chemotherapy with 5-FU after which her performance status deteriorated and became unfit for chemotherapy and subsequently she succumbed to the disease 3 months following surgery.

#### **DISCUSSION:**

GISTs represent a subgroup of gastrointestinal mesenchymal tumors arising from a common precursor cell, the interstitial cell of Cajal, or a primitive stem cell from which both Cajal cells and smooth muscle cells arise (1). GISTs strongly express (90-95%) the KIT (CD117) protein, a type III tyrosine kinase receptor encoded by c-KIT proto-oncogene. Approximately 70% of GISTs are positive for CD34, 30-40% are positive for smooth muscle actin (SMA), 10% for S-100 protein and <5% for desmin (1-3). GISTs typically occur in older individuals. Most GISTs arise from the stomach (50–62%), from the small intestine (20–30%), the colon (11%), the rectum (7%) while the esophagus is rarely involved (0.6–1%). GISTs' malignant potential is considered to depend on tumor size, frequency of mitoses, presence of necrosis, and the possible invasion to adjacent organs. The coexistence of GISTs with other neoplasms is rare but more common than was previously considered and the rate is between 11 to 33%. There are some case reports and case series about the coincidence of GISTs with gastrointestinal adenocarcinomas, adenocarcinoma arising in villous adenoma of the ampulla of Vater, mucosa-associated lymphoid tissue lymphoma, carcinoid tumor, duodenal Brunner's gland adenoma, neurofibroma, and somatostatinoma of the ampulla of Vater. However this is the first case of GB adenocarcinoma in a patient with GIST. Although the synchronous occurrence of GIST and other abdominal malignancy seems to be just a coincidence, combined genetic deregulation or influenced neighboring tissues by the same carcinogen could be causative factors. There are some data regarding the co-occurrence, the association and the potential comm. on origin (genetic pathways of tumorigenesis), between GIST and other tumors (4). However, there are no significant differences in the immunohistochemical and molecular profile between single GISTs and GISTs coexisting with other tumors and no mutational correlation between the GISTs and the coexistent tumors of different histogenesis regarding the *KIT* and *PDGFRA* genes (5). *The limited number of these cases cannot confirm the existence of a common factor in tumorigenesis of these histopathologically completely different tumors and further studies are needed to clarify the possible association.*

#### **CONCLUSION:**

The coexistence of GIST with either synchronous or meta-chronous gastrointestinal adenocarcinomas represents a phenomenon with increasing number of relative reports in the literature over the last 5 years. In any case of GIST (with or without preoperative histopathological confirmation) the surgeon should be alert to recognize a possible coexistent tumor with different histological origin and perform a thorough preoperative and intraoperative search. The correct diagnosis before and at the time of the surgical procedure is the cornerstone that secures the patients' best prognosis.

#### REFERENCES:

- 1 Miettinen M, Lasota J: Gastrointestinal stromal tumors – definition, clinical, histological, immunohistochemical, and molecular genetic features and differential diagnosis. *Virchows Arch* 2001, 438:1-12.
- 2 Miettinen M, Sarlomo-Rikala M, Sobin LH, Lasota J: Gastrointestinal stromal tumors and leiomyosarcomas in the colon: a clinico-pathologic, immunohistochemical, and molecular genetic study of 44 cases. *Am J Surg Pathol* 2000, 24:1339-1352.
- 3 Fletcher CD, Berman JJ, Corless C, Gorstein F, Lasota J, Longley BJ, Miettinen M, O'Leary TJ, Remotti H, Rubin BP, Shmookler B, Sobin LH, Weiss SW: Diagnosis of gastrointestinal stromal tumors: a consensus approach. *Int J Surg Pathol* 2002, 10:81-89.
- 4 Kosmidis C, Efthimiadis C et al: Synchronous colorectal adenocarcinoma and gastrointestinal stromal tumor in Meckel's diverticulum; an unusual association. *World J Surg Oncol*. 2009, 7:33.
- 5 Arnogiannaki N et al: Synchronous presentation of GISTs and other primary neoplasms: a single center experience. *In Vivo*. 2010, 24(1):109-15.