



## Cementifying Fibroma of Maxilla – A Case Report

Srikamakshi Kothandaraman   Balasubramanian Thiagarajan  
Stanley Medical College

### Abstract:

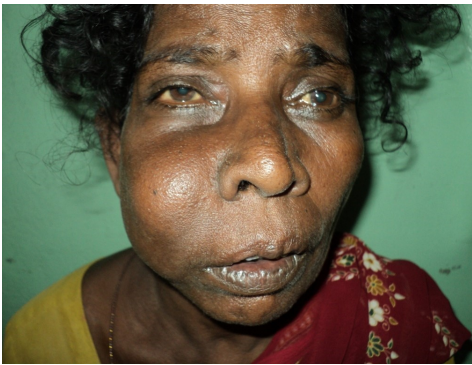Cementifying Fibroma is a benign fibro-osseous lesion of the jaw bones. It arises from the mesenchymal cells of the periodontal ligament. It is a common occurrence in the mandible, and quite rare in the maxilla. It is usually a slow growing, well-circumscribed mass encountered in the middle-aged adult (with female sex predilection).

The most closely related differential diagnosis for this condition is fibrous dysplasia (apart from the other histo-pathological variants of this condition such as Ossifying Fibroma, Cemento-Ossifying Fibroma). The two conditions differ in their radiological presentations, approach to their management and natural history of the disease (with and without treatment).

The clinical, radiological and histo-pathological features of a patient with Cementifying Fibroma of the Right Maxilla who presented herself in our Out-Patient Department has been described along with a detailed account of the treatment plan adopted for her. An elaborate discussion follows, based on review of literature.

## Case Report:

A 50 years old female patient came to our ENT OPD with complaints of swelling over the right side of her face for the past 3 years. The swelling had apparently been small in size initially and had slowly progressively increased in size to attain the current size.



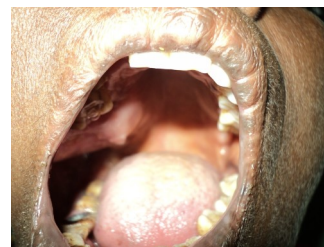Clinical Photograph of the patient

There was no history of pain over the swelling or any oral/nasal bleed. There was no history of difficulty in breathing/nasal block. There was no history of difficulty in opening the mouth. There was no history of any facial pain/epiphora. The patient gave history of trauma to the face about 4 years back by accidental fall. There was no history of any tooth extraction. She gave history of shaky and falling teeth of the maxillary region on the right side over the last 1 year.

There was no history of difficulty in swallowing/voice change/aspiration. There was no history of ear block sensation/ earache/ ear discharge/ hard of hearing.

On examination, a 6x6 cm swelling was seen over the region of the right maxilla with well defined edges. The skin over the swelling appeared to be normal. On palpation, the swelling was found to be firm to hard in consistency, not warm, not tender, immobile. The skin over the swelling was pinchable. There was no infra-orbital nerve hypoesthesia/anaesthesia bilaterally. The naso-labial groove was intact on both sides. Corneal sensations were intact and extra-ocular movements were full bilaterally. There was no significant lymphadenopathy on examination of the neck. Carotids were palpable bilaterally and trachea was found to be in the mid-line.

Examination of the oral cavity revealed a smooth bulge on the right side of the hard palate.

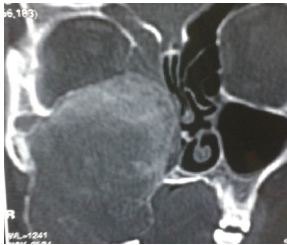


Intraoral picture of the patient

Premolars and molars were missing in the right maxillary region. Sub-labially also, a firm to hard mucosa covered swelling was seen over the gingiva in the region of the right canine fossa. No other significant abnormality was noted on examination of the rest of the oral cavity and oropharynx and both ears.

Examination of the nose –Anterior Rhinoscopy- there was a spur to the left near the floor. No other significant abnormality was noted.

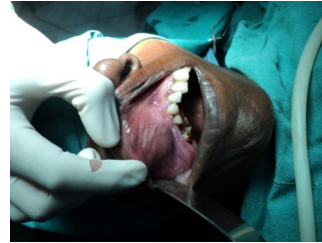DNE- The right lateral nasal wall was pushed inwards into the right nasal cavity. There was a spur to the left near the floor. No other significant finding/abnormality was noted.



CT PNS

It is seen that the mass is completely filling the right maxillary sinus. Posteriorly, it is seen that the mass is pushing the lateral nasal wall medially and also pushing the hard palate into the oral cavity.

In order to arrive at a definite diagnosis, a Caldwell-Luc procedure was planned.

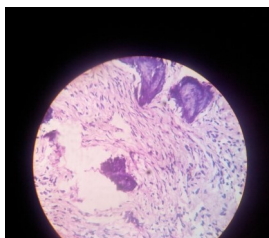


Biopsy was taken from the mass (which was found to be firm to hard) through the right canine fossa and sent for Histo-Pathological Examination.

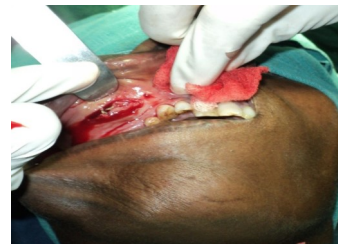

Figure showing the Incision

The biopsy report came as Cementifying Fibroma - "the section shows fibrous cells with basophilic aggregates of cementum."



Picture showing histopathology of the lesion

So we decided to proceed with Excision of the mass under General Anaesthesia. After obtaining fitness for anaesthesia, the patient was posted for surgery. Classical Weber-Fergusson incision was marked and made after performing temporary tarsorrhaphy.

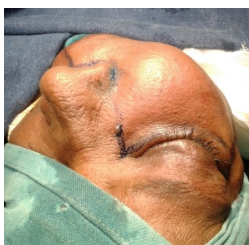

Figure showing weber ferguson Incision

The incision was deepened upto the level of the periosteum and flap was elevated which exposed the mass immediately.

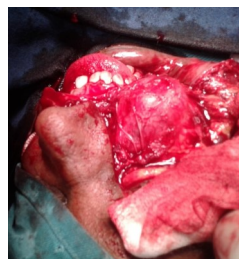

Figure showing the mass exposed

The bony cuts were made:

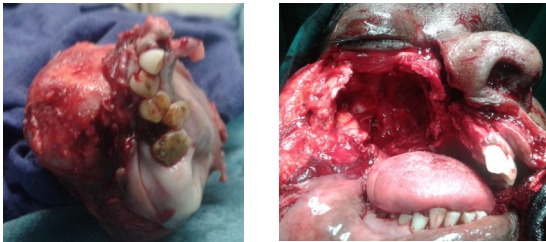
1. Along the fronto-ethmoidal suture line and frontal process of maxilla

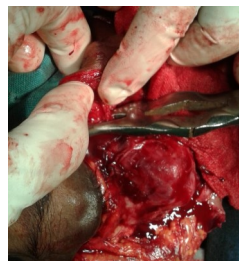

Figure showing the first bone cut

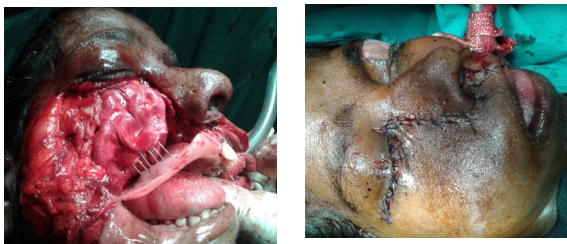2. Along the full length of the hard palate to the right of the midline
3. Along the floor of the pyriform aperture on the right side
4. At the lateral end of the right inferior orbital fissure along the maxillo-zygomatic suture line.

These cuts enabled the mass to be removed in toto along with the teeth attached to it (incisors, canine and premolar) and walls of the maxilla (antero-lateral, floor, medial walls). The posterior wall of the maxilla was left in situ.



Figures showing the mass and the wound after removal of mass

Gutta percha was moulded to fit the cavity and the obturator ( already designed by the Dental Surgeons) was fixed in place.



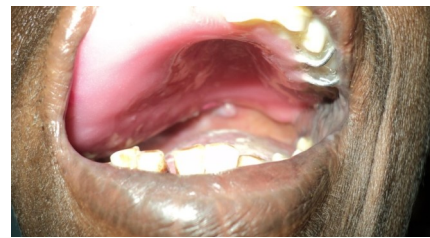Figures showing the placement of Gutta percha and the closed wound

Complete haemostasis was secured. The wound was closed in layers. The tarsorrhaphy was released. Dressing was applied.

The patient was extubated and shifted to ward after observation.

The post-operative period was uneventful. The sutures were removed after 1 week.

The patient was reviewed periodically in the Dental Out-Patient Department to ensure good fit of the prosthesis. Oral hygiene was stressed.



Intraoral view of Guttapercha

#### DISCUSSION:

Fibro-Osseous lesions of the Jaw is a group of conditions, which is remarkable for its clinico-pathological similarities.<sup>1</sup> The term fibro-osseous lesion is a generic designation given to a group of jaw disorders that microscopically exhibit a connective tissue matrix and islands of trabeculae of bone.<sup>1</sup>

The term fibro-osseous lesion does not refer to a concrete diagnosis but rather to a group of pathological processes with similar radiological appearances and histopathologies<sup>30</sup>.

Lesions with fibrous and osseous components include fibrous dysplasia (FD), ossifying fibroma (OF), cementoossifying fibroma (COF) and cementifying fibroma (CF). Fibro-osseous lesions other than FD seem to have origin from the periodontal membrane.<sup>2</sup>

this group of lesions is best considered to be a spectrum of processes arising from cells in the periodontal ligament and having the potential to form bone, cementum, and fibrous tissue in varying proportions and combinations. Some of these lesions are obviously reactive in nature, while others seem to be neoplastic.<sup>10</sup>

#### CLASSIFICATION OF FIBRO-OSSEOUS LESIONS

<sup>4,12,31</sup> .

Classification of fibro-osseous lesions: (Waldron, 1985)

##### 1. Fibrous dysplasia

a) polyostotic

b) monostotic

2. Fibro-osseous or cemental lesions presumably arising in the periodontal ligament

a) periapical cemental dysplasia

b) localized fibro-osseous cemental lesions

c) florid cemento-osseous dysplasia (gigantiform cementoma)

d) Ossifying and cementifying fibroma

3. Fibro-osseous neoplasms of uncertain or debatable relationship to those arising in the periodontal ligament

a) Cementoblastoma, osteoblastoma and osteoid osteoma.

b) Juvenile active ossifying and the so called active ossifying cementifying fibroma

#### WHO classification :

The first World Health Organization (WHO) 'Histological Typing of Odontogenic Tumours, Jaw Cysts and Allied Lesions,' published in 1971 includes odontogenic tumors and tumor-like lesions, jaw cysts & certain bone lesions that are either peculiar to the jaws or have distinctive features when they occur in that location.

The WHO classification of 1971 used the concept of cementomas to group together lesions containing cementum-like tissue, thus forming a complex group including both neoplastic (benign cementoblastomas, cemento-ossifying fibromas) and non-neoplastic lesions (periapical cemental dysplasias, gigantiform cementomas).

According to the second WHO classification of 1992, benign fibro-osseous lesions in the oral and maxillofacial regions were divided into two categories, osteogenic neoplasm and non-neoplastic bone lesions thus clearly separating neoplastic from non-neoplastic lesions containing cementum-like tissue. Cementifying ossifying fibroma belonged to the former category.

During the 2003 Consensus Conference, held in conjunction with the preparation of the new WHO Volume on Tumors of the Head and Neck, some changes were made. Osseous neoplasm and non-neoplastic lesions were categorized under the section "Neoplasms and Other Lesions Occurring in the Maxillofacial Skeleton." The section on osseous neoplasms included ossifying fibroma (formerly cemento-ossifying fibroma) and the section on non-neoplastic lesions comprised of fibrous dysplasia, osseous dysplasias, central giant cell lesion/granuloma, cherubism, aneurismal bone cyst and simple bone cyst<sup>31</sup>.

However, the term "cementifying ossifying fibroma" was changed to ossifying fibroma (OF) in the new WHO classification in 2005.

## HISTORY<sup>31</sup>:

Yih et al. and Sciubba et al. attributed the first description of this disorder to Menzel, in 1872. Montgomery appears to have been the first to designate jaw lesions of this type as ossifying fibromas, by which the lesion is currently known. Lack of standardized terminology and classification of central or intraosseous cemento-osseous lesions of the jaws has long posed a dilemma for histopathologists and clinicians. Until 1948 it was believed that fibrous dysplasia and ossifying fibroma were either the same entity or variant of the same lesion, when Sherman and Sternberg published a detailed description of the clinical, radiological and histological characteristics of ossifying fibroma. This clearly proved that the two lesions were different clinical entities. Jaffe originally believed these lesions were monostotic manifestation of fibrous dysplasia, although 5 years later he himself concluded that the ossifying fibroma, which he called fibrocementoma, was a separate entity from fibrous dysplasia.

## SOME IMPORTANT TERMS:

### Periodontal ligament<sup>2,28</sup>:

This is a layer of fibrous connective tissue surrounding the roots of teeth. It contains multipotential cells capable of forming cementum, lamellar bone and fibrous tissue. Under pathological conditions neoplasms containing any or all of the components may be produced.



Because all cementum containing lesions are theoretically of periodontal membrane origin, maxillary sinus spread after origin from upper premolar or molar teeth is a distinct possibility.

The fibrous connective tissue of the periodontal membrane is composed of collagen, oxytalan fibers, and mucopolysaccharides which has the capacity to produce bone, cementum, and fibrous tissue. These blastic cells under pathological conditions can produce tumors related to bone, cementum, and fibrous tissue.

Cementum<sup>7</sup>:

Cementum is the hard mineralised substance that covers the viable dental root. It is a specialised connective tissue that shares physical, chemical and structural characteristics with compact bone, but differs from it by its avascularity.

**CEMENTIFYING FIBROMAS:** <sup>1,5,30,31,33</sup>

This is a rare benign non-odontogenic tumours of the jaw & facial bones. Cementifying fibroma is a distinctive jaw lesion and has its origin from the periodontal membrane that has the characteristic feature of cementum formation. Hence it is also known as periodontoma . One of its principal characteristics is the massive formation of cementum, cementoid substance or calcified material in the interior of a predominantly fibrous tissue.

The term cementifying fibroma has been applied to lesions containing curvilinear trabeculae and spheroidal calcifications (Cementum). The cementifying fibroma may occur at any stage, but is more common in older subjects, either jaw may be involved, but it usually occurs in the mandible. A common occurrence in the premolar-molar area of the mandible, it has also been reported in the orbital and petromastoid regions, and the maxillary, ethmoidal, frontal and sphenoidal sinuses too.

The growth pattern of the mass is centrifugal so grows equally in all directions presenting therefore as a well circumscribed mass. They maintain a spherical shape, expand the surrounding cortical bone without cortical perforation, and may cause tooth divergence.

It is usually well circumscribed, generally grows slowly and occurs more frequently in females. A review of literature disclosed a small number of cases that showed aggressive behavior and recurrences, the recurrences were related to the inherent biologic behavior of the tumor rather than to insufficient surgical removal.<sup>1</sup> Histologically the calcified product in some cases consists of almost entirely of amorphous, basophilic, usually rounded calcifications commonly considered to be cementum.<sup>1</sup> Histological pattern varies with the stage of development, being predominantly cementum like as the rounded masses enlarge and fuse together.



Some fibromas show, grossly and microscopically, a fibrous capsule surrounding the tumor. Most are not encapsulated but are well demarcated grossly and microscopically from the surrounding bone.

Radiographically, the lesion usually has a distinct boundary and in the early stages, it presents as a lucent area. As the lesion matures, bone densities appear, transforming the lesion into a radio-paque mass surrounded by a "halo" of less ossified tissue. A significant point is that the outer cortical plate, although displaced and thinned, remains intact. The lamina dura of involved teeth usually is missing, and resorption of teeth may occur.

Some authors have suggested that all the fibro-osseous lesions relating to cemento-ossifying fibroma and its subtypes should be referred to as ossifying fibroma only since they claim that there is no difference in behavior between the subtypes and the histological designations are only academic.

#### ETIOLOGY & PATHOGENESIS<sup>1,7,15,18,28,31,32</sup>

The etiology and pathogenesis of fibro-osseous lesions still remains a subject of investigation. Various theories have been offered, such as, congenital anomaly of bone, developmental defect caused by faulty embryogenesis, hamartoma, tumour of periodontal membrane origin, mesenchymal tumour arising in spongiosa and an abnormal repair of bone after injury.

The fact that COF is most common in the jaw bones is related to the vast amount of mesenchymal cellular induction into bone (lamina dura) and cementum in odontogenesis. Hence the probability of induction error or genetic mutation leading to neoplasm is higher.

#### PREDISPOSING FACTORS:

Some triggering mechanisms for formation and deposition of cementum outside the periodontal ligament are – infection with resulting inflammation and fibrosis, trauma, dental extractions. Trauma as a triggering factor suggests that this condition is a connective tissue reaction rather than a neoplasm. Wenig et al. has suggested that trauma-induced stimulation may play a role.

Most reports suggest that there must be a history of previous trauma in the area of the lesion. Many authors have agreed that infection and dental extraction stimulate the periodontal membrane to produce and deposit cementum.

#### CONTROVERSIES OVER ORIGIN

A marked female predilection has been observed, with majority of the cases arising in the molar-premolar region of the mandible. Radiographically, these neoplasms are well demarcated and may be radiolucent, radiolucent with central opacification (target appearance), or multilocular radiolucent.

A benign fibro-osseous histopathologic pattern is observed with osseous, cemental, and/or ovoid-curvoid calcified deposits. This feature, along with confinement to tooth-bearing regions, supports a periodontal ligament origin.

However there is controversy over such an origin (from the mesenchymal blast cells of the periodontal ligament), since tumors of similar histology have been reported in bone lacking periodontal ligament and not located in the maxillary region, such as ethmoid bone, frontal bone or even long bones of the body (cementiform fibrous dysplasia). Microscopically identical neoplasms with cementum-like differentiation have also been reported in the orbital, frontal, ethmoid, sphenoid and temporal bones as well as nasopharynx and paranasal sinuses, thus questioning this theory of origin<sup>19</sup>.

#### CEMENTIFYING AND OSSIFYING FIBROMAS : SIMILARITIES AND DIFFERENCES<sup>1,2,15,31</sup>

Bhaskar has warned that cementifying fibromas are in reality, ossifying fibromas, in which the bone tissue appears basophilic and resembles cementum superficially. Cementifying fibromas and ossifying fibromas are two distinct benign neoplasms representing two facets of the same tumor (Shafer et al).<sup>1</sup> Although the WHO classifies the cementifying fibroma as an odontogenic tumor and ossifying fibroma separately as non-odontogenic neoplasm, this distinction seems arbitrary and unnecessary, as the clinical, radiologic and prognostic features of the two lesions are identical.

In some cases, most of the calcified fragments are immature cementum, with basophilic coloration on hematoxylin and eosin-stained sections. These tumors are called central cementifying fibroma.

In other cases, the calcified fragments are osteoid, with typical eosinophilic coloration on hematoxylin and eosin-stained sections. These tumors are called central ossifying fibromas. However, central ossifying fibromas can also be basophilic, causing difficulties in differentiating them from central cementifying fibromas. Most pathologists feel that central cementifying fibromas and central ossifying fibromas arise from the same progenitor cell but produce variable amounts of bone and cementum within any one lesion.

Large lesions that increase in size to over 80 mm in their greatest diameter have been termed as 'giant ossifying fibroma'. Ossifying fibromas consist of fibrous tissue that exhibits varying degrees of cellularity and contains mineralized material.

According to the 1992 World Health Organization (WHO) classification, an ossifying fibroma is a "demarcated or rarely encapsulated neoplasm consisting of fibrous tissue containing varying amounts of mineralised material resembling bone and/or cementum". Ossifying fibroma is a part of benign fibro-osseous lesions of the jaw that are characterized by replacement of normal bone by fibrous tissue containing a newly formed mineralized product.

Ossifying fibromas are usually solitary, but bilateral as well as multiple familial ossifying fibromas have also been reported.

#### CEMENTO-OSSIFYING FIBROMA<sup>1,2,19,25,28,30,33</sup>

A significant number however contain an admixture of the two types of calcifications and are often grouped as “cementoossifying fibromas”. The hybrid name central cemento-ossifying fibroma is used because we are discussing about a spectrum of fibro-osseous lesions that arise from the periodontal ligament, ranging from those with only deposition of cementum to those with only deposition of bone.<sup>2</sup> Central cementoossifying fibromas are asymptomatic until they cause expansion. Thus, they are generally not diagnosed until the tumour has had time to produce calcifications.

Large tumors may involve the nasal septum, orbital floor, and infraorbital foramen. Pathologic examination of the central cementoossifying fibroma shows a proliferation of irregularly shaped calcifications within a hypercellular fibrous connective tissue stroma.

The calcifications are extremely variable in appearance and represent various stages of bone and cementum deposition. The hard tissue portions consist of trabeculae of osteoid and bone or basophilic and poorly cellular spherules that bear a resemblance to cementum.

The bony trabeculae vary in size and often demonstrate a mixture of woven and lamellar patterns. Peripheral osteoid and osteoblastic rimming are usually present. The spherules of cementum-like material often demonstrate peripheral brush borders that blend in to the adjacent connective tissue. Significant intralesional hemorrhage is unusual.

The hybrid central cementoossifying fibroma has evolved to indicate the difficulty in being able to distinguish reliably immature bone from immature cementum and because of the presence of both of these substances in many of the lesions

Intra-cranial extension of the tumour (when it occurs in the orbit) has also been documented. COF can affect any part of the cranio-facial skeleton. male to female ratio is around 1:5.

Clinical differential diagnoses:

Stafne's idiopathic bone cavity simulated chronic periapical infectious pathology.

Two basic radiological patterns: a unilocular radiolucency with or without radiopaque foci and a multilocular radiolucent configuration. The margin of the lesion is relatively well defined and shows the presence of sclerotic rim in the host bone as a result of peripheral osteocondensation.

Histopathologically, it is typical to encounter a benign fibroblastic stroma with varying cellularity, although mitosis is rare. Within the fibrous stroma there are mineralized tissue masses of basophil aspect that correspond to osteoid or cementoid material.

The mandibular molar and premolar is the common site. Aggressive lesions usually involve the maxillary antrum. COF of the head and neck is described radiographically as a well-circumscribed expansile lesion with calcified matrices in the maxilla and mandible.

#### MAXILLARY AND MANDIBULAR COF <sup>2,4</sup>:

Central cemento-ossifying fibromas of the mandible are common, whereas central cementoossifying fibromas of the maxillary sinus are unusual tumors. Maxillary central cementoossifying fibromas are large at the time of presentation, indicating the capacity of the tumor to expand freely within the maxillary sinus. Maxillary lesions are more immature than the mandibular ones<sup>2</sup>. Central cementoossifying fibromas usually 'shell out' easily at surgery, but maxillary central cementoossifying fibromas are more difficult to remove completely than mandibular central cementoossifying fibromas. This may be attributable to the difference in bone character between the mandible and maxilla and to the available space for expansion in the maxillary sinus. COF in the maxilla most commonly appears in the canine fossa and zygomatic arch area.

#### RADIOGRAPHIC FEATURES <sup>28,30,31,33</sup>

Cementifying fibroma has often been described as a well-defined expansile lesion on CT-PNS. The classical 'punched out appearance' and 'egg shell expansion' of the tumor can sometimes be appreciated in the CT scan.

The presence of well-defined margin was held by Sciubba and Younai to be consistent and reliable radiological marker for ossifying fibroma.

MacDonald-Jankowski described three stages in the radiographic appearance. Initially the lesion is radiolucent (osteolytic image), which then becomes progressively radiopaque as the stroma mineralizes thus transforming in to mixed lesion. Eventually, the individual radiopacities coalesce to the extent that the mature lesion may appear sclerotic or radiopaque lesion.

Three different patterns of radiographical borders were reported by Su et al : A defined lesion without a sclerotic border, a well-defined lesion with a sclerotic border, and a lesion with an ill-defined border . The CT films of some patients have shown that the border of the lesion is completely well-defined but the outer shape of sinus walls has changed. A cotton-wool appearance in the internal structure has been seen.

Six distinct radiographic patterns have been identified:

- (1) radiolucent, superimposed over teeth or residing in edentulous regions
- (2) radiolucent with opaque foci, lying in edentulous areas or superimposed over teeth
- (3) radiolucent, interposed between contiguous teeth
- (4) radiolucent with opaque foci, interposed between contiguous teeth
- (5) multilocular expansile and
- (6) aggressively expansile with opacification

#### ASSOCIATED CONCOMITANT SECONDARY LESIONS<sup>27,33</sup>:

Aneurysmal bone cysts (ABC) are osteolytic lesions containing blood filled spaces. They can present either as a primary lesion by itself or as a secondary change in a pre-existing lesion. Cases of JOF with secondary ABC like areas, though uncommon, have been reported in earlier literature. The importance of such presentation lies in the fact that cases of JOF associated with secondary ABC tend to show a more aggressive growth pattern and greater recurrence potential. Such hybrid lesions are also more difficult to treat. Due to the possibility of the occurrence of such hybrid lesions, it is preferable to remove the tumour en-masse and take multiple sections for histopathological reporting.

#### JUVENILE AGGRESSIVE CEMENTO-OSSIFYING FIBROMA<sup>2,19,27,31,33</sup>

When this tumor arises in children, it is called the juvenile aggressive cemento-ossifying fibroma. It is more aggressive clinically and more vascular at pathological examination. Juvenile ossifying fibroma has been further classified into 2 separate subtypes as psammomatoid and trabecular ossifying fibroma. Psammomatoid ossifying fibroma of the paranasal sinuses has been considered as an extragnathic variant of cemento-ossifying fibroma by some authors. The preferred sites are the maxilla, ethmoid and the frontal bones. The term 'active' refers to clinical aggression such as bone erosion, soft tissue invasion and in rare instances death.

The most common clinical finding is proptosis. Other symptoms include nasal obstruction, headache, swelling and rarely epistaxis. The most distinctive component in these lesions (Even though not pathognomonic) is the presence of calcified ossicles containing osteocytes known as 'psammomatoid bodies'. Because of a superficial resemblance between these ossicles and the cementum spheres of the odontogenic ossifying fibroma, the lesion has sometimes been mislabeled as cemento-ossifying fibroma, implying an odontogenic origin, which is rather unlikely in extragnathic bone. Hence Psammomatoid bodies have been synonymously referred to as 'cementicles' by some authors.

The juvenile (aggressive) ossifying fibroma (JOF) mainly affects individuals younger than 15 years of age. It behaves in an aggressive fashion when compared to ossifying fibroma.

JOF is commoner in the maxilla than in the mandible. Their distinct clinical and histopathological features warrant the lesion to be considered as a separate entity from other fibro-osseous group of lesions such as fibrous dysplasia and cemento-ossifying fibroma.

It is described in WHO classification as

“an actively growing lesion consisting of a cell-rich fibrous stroma, containing bands of cellular osteoid without osteoblastic rimming together with trabeculae of more typical woven bone. Small foci of giant cells may also be present, and in some parts there may be abundant osteoclasts related to the woven bone. Usually no fibrous capsule can be demonstrated, but like the ossifying fibroma (and unlike fibrous dysplasia), the JOF is well demarcated from the surrounding bone.”

#### SPECIAL CASE REPORTS<sup>6,11,14,16,24,25,27,31,32,34</sup>

There have been a few reports of cementifying fibromas following an aggressive course (especially among the young) amidst the many reports of the benign nature of this lesion. Some unique reports:

A case of Juvenile – aggressive cemento-ossifying fibroma of the ethmoidal and sphenoidal sinuses with secondary maxillary and frontal sinusitis has been reported.

Heterodense lesion was seen on CT with intracranial extension. Modified lateral rhinotomy approach was used to remove sino-nasal component, and bicoronal flap to remove intracranial component<sup>6</sup>.

A case involving a 35-year-old man with massive, bilateral, slow-growing ossifying fibromas in the maxillary sinuses resulting in facial deformity and orbital compression has been reported in literature<sup>11</sup>.

COF in a 70 year old female. No recurrence was observed in a 5-year follow up period<sup>14</sup>.

A case of multiple central ossifying fibroma in a 35 year old woman can be found in literature. The lesion recurred in different locations after 15 years<sup>32</sup>.

Psammomatoid Ossifying Fibroma in a 10 year old: It involved the maxillary sinus with intracranial extension. When it recurred, it was much more aggressive in nature.

A rare case of ossifying fibroma arising in the maxilla of an 11-year-old child was treated with enucleation<sup>31</sup>.

A rare case of –large frontoethmoidal mucocoele associated with cemento ossifying –fibroma of the anterior ethmoids, observed in a young female, aged 21 years, and surgically treated, has been reported<sup>24</sup>.

The mass was involving the anterior part of hard palate in the midline and extending bilaterally displacing the upper molars and premolars and had effaced the gingivolabial sulcus. On its outer surface there were multiple pus points. It was non-tender, but bled on touching. The contrast enhanced CT scan showed an expansile lytic lesion with osseous fragments involving the anterior 1/3 of the hard palate and alveolar ridge. Anteriorly, it involved the right nasal passage abutting the inferior turbinate and blocking the airway. COF of aggressive type was diagnosed on biopsy and patient underwent resection of the tumour via mid facial degloving approach<sup>25</sup>.

There has been a report of a case of a young girl who was diagnosed with aneurysmal bone cyst during her 1st presentation at a private hospital and was treated for the same. The lesion recurred within 6 months. The second incisional biopsy specimen revealed features of trabecular variant of juvenile ossifying fibroma along with areas of aneurysmal bone cyst<sup>27</sup>.

#### DIFFERENCES BETWEEN CEMENTIFYING FIBROMA AND FIBROUS DYSPLASIA<sup>1,19,28</sup>

Fibrous dysplasias are basically a non-pathologic entity with unknown etiology. They are the outcome of disturbances in the normal growth pattern.

Cementifying and ossifying fibroma may be seen with a similar mottled appearance to that seen in fibrous dysplasia. The following differences are recognized radiologically between COF & FD:1

1. Shape: the cementifying and ossifying fibromas are predominantly round while fibrous dysplasia is more rectangular.
2. Jaw expansion: jaw expansion caused by cementifying and ossifying fibroma is usually nodular or dome shaped whereas the jaw expansion of fibrous dysplasia is usually of the elongated fusiform type.
3. Margins: cementifying and ossifying fibromas have sharply defined radiographic margins. In contradistinction, the margins of fibrous dysplasia are indistinct, blending imperceptibly with normal bone.
4. Predominant jaw: approximately 70% of cementifying and ossifying fibromas occur in the mandible. Fibrous dysplasia shows a slight predilection for the maxilla.
5. Age : The age range for ossifying fibromas is from 7 – 58 years. The majority of active case of fibrous dysplasia is found in patients under 20 years of age.

Distinguishing between ossifying fibroma and fibrous dysplasia is the primary diagnostic challenge. Both lesions may exhibit similar clinical, radiographical and microscopic features. The most helpful feature in distinguishing the two is the well-circumscribed radiographical appearance of ossifying fibroma and the ease with which it can be separated from the normal bone. In most cases the well-defined appearance of ossifying fibroma is evident radiographically.



Fibrous dysplasia has a blending margin with the surrounding bone and has a linear expansion of the cortex. The expanded cortex cannot be in exact parallel relationship, thereby failing to produce a round tumor mass which is seen in COF.

Historically, differentiating the two lesions was based primarily on histological criteria. Fibrous dysplasia was reported to contain only woven bone, without evidence of osteoblastic rimming of bone. The presence of more mature lamellar bone was believed to be characteristic of ossifying fibroma. Variation in the types of mineralized material produced may be helpful in distinguishing ossifying fibroma from fibrous dysplasia. Most authorities now acknowledge that these criteria are unreliable, because both types of bone and cellular features may be found in either lesion.

#### DIFFERENTIAL DIAGNOSES <sup>1,2,19,28</sup>

As it has varied radiographic appearance, a fibro-osseous lesion must be considered in the differential diagnosis of almost all radiolucent, radiopaque or radiopaque-radiolucent lesions of the jaw bones.

Ossifying fibroma with a completely radiolucent lesion:

cemento-osseous dysplasia (early stage),  
odontogenic cyst,  
periapical granuloma, traumatic bone,  
ameloblastoma

central giant cell granuloma.

Differential diagnosis for mixed radiographical feature: (including lesions which have radio opacities within a well-defined radiolucent mass)

Fibrous dysplasia

Chondro/osteosarcoma

Squamous cell carcinoma

Chronic sclerosing osteomyelitis

calcifying odontogenic cyst (Gorlin cyst),

adenomatoid odontogenic tumor,

rarefying and condensing osteitis,

cemento-osseous dysplasia,

calcifying epithelial odontogenic tumor (Pindborg tumor),

odontogenic fibroma

ameloblastic fibro-odontoma.

Furthermore, ossifying fibroma with completely radiopaque radiographical features:

retained root,

odontoma,

idiopathic osteosclerosis,

condensing osteitis,

cemento-osseous dysplasia (late stage)

osteoblastoma.

Ossifying fibroma of a very large size may be misdiagnosed as osteogenic sarcoma<sup>19</sup>.

Giant cell reparative granuloma must be considered in the differential diagnosis of fibro-osseous lesion because of the presence of giant cells in both the lesions.

Chronic scalloping osteomyelitis, osteogenic sarcoma, chondrosarcoma, Ewing's sarcoma, must be differentiated from mottled type of fibro-osseous lesion.

Other conditions which may resemble fibro-osseous lesion include osteoblastoma, osseous dysplasia, odontogenic myxoma, osteogenesis imperfect, Paget's disease.<sup>1</sup>

The well-defined border of the central cemento-ossifying fibroma helps differentiate it from aggressive sarcomas and carcinomas.

Fibrous dysplasia has a characteristic 'Ground-Glass' appearance, not seen in the central cemento-ossifying fibroma.

The radiologic differentiation of central cemento-ossifying fibroma from Gorlin cysts

and Pindborg tumors is difficult. The final diagnosis is based on histologic appearance.

Pindborg tumors have a high association with impacted teeth, and give an appearance of 'driven-snow' in the radiographs.

Osteoblastoma is evident in slightly younger age group and is often characterised by pain. The osseous trabeculae in these lesions are rimmed by abundant plump osteoblasts, but the supporting stroma is loosely fibrovascular with dilated channels and focal hemorrhagic areas.

Periapical cemento-osseous dysplasia in posterior teeth may appear radiographically similar and require a biopsy to separate it from ossifying fibroma.

Focal osteomyelitis is associated with a source of inflammation and is possibly accompanied by pain and swelling<sup>19</sup>.

Cemento-osseous dysplasia show the presence of bony cysts with a wide sclerotic border. Also cemento-osseous dysplasia is multifocal while COF is not<sup>28</sup>. Vitality test will help in differentiating the COF from condensing osteitis.

Odontoma will show presence of tooth-like structure whereas COF shows a radiopaque foci<sup>28</sup>. PERIPHERAL CEMENTIFYING FIBROMA<sup>9</sup>  
This is a solitary growth on the gingiva. It arises from the soft tissues overlying the tooth bearing areas of the jaw, often arising from the interdental papillae. DD: pyogenic granuloma, peripheral giant cell granuloma. It is possibly a response to irritation. Recurrence is a problem (upto 20%) due to persistence of irritant factors.

COF, POF, COdF, POdF<sup>20</sup>

In 1982, Gardner coined the term peripheral ossifying fibroma for a lesion that is reactive in nature and is not the extraosseous counterpart of a central ossifying fibroma (COF) of the maxilla and mandible. There are two types of ossifying fibromas: the central type and the peripheral type. The central type arises from the endosteum or the periodontal ligament adjacent to the root apex and causes the expansion of the medullary cavity. The peripheral type occurs solely on the soft tissues covering the tooth-bearing areas of the jaws. COF was found to exhibit increased proliferative activity compared to POF. Peripheral odontogenic fibroma (POdF) has been designated by the World Health Organization (WHO) as the rare and extraosseous counterpart of central odontogenic fibroma (COdF) and histologically presents as a fibroblastic neoplasm containing odontogenic epithelium.

#### MANAGEMENT<sup>2,23,28,33</sup>

The recommended treatment modality for the central cementoossifying fibroma is excision. The entire tumor should be removed including involved regions of the orbital floor and maxillary sinus walls. It is mainly done by enucleation of small-sized ossifying fibromas and mono-bloc resection with bone reconstruction for larger sized cement-ossifying fibromas.

Peripheral ossifying fibroma (POF)	Central ossifying fibroma (COF)	Peripheral odontogenic fibroma (POdF)	Central odontogenic fibroma (COdF)
Nature	Reactive lesion	Fibro-osseous lesion	Odontogenic tumor
Site	Mostly on gingiva	Wide-spread lesion in the long bones but may also occur in the skull and jaw bones	Gingiva, but occurrence is rare
Classification	No subtypes	Two types: 1) Psammomatoid 2) Juvenile type	Histologically the same as COdF; contains odontogenic epithelium
Interrelation	Not the extraosseous counterpart of COF	Presents centrally – a separate entity from POF	Extraosseous counterpart of COdF

Various radical and semi radical resection procedures have been tried for the extensive aggressive forms of this lesion. Fronto-parietal craniotomy with cranioplasty has been done for lesions of the parietal bone. Similarly partial mandibulectomy followed by plate fixation has been done for mandibular lesions. Extensive bilateral tumors require combined multiple approaches whereby the tumour is excised portion by portion.

Bilateral nasal tumours have been removed by modified lateral rhinotomy with bilateral ethmoidectomy and sphenoidotomy. Larger lesions with intracranial extension may require en bloc resection or craniofacial resection. The Lynch Howarth approach has been particularly useful to relieve proptosis when the tumour was confined only to the medial portion of the orbit and the ethmoid. The extended Caldwell Luc approach and sublabial approach are more suitable for lesions involving the maxilla and the premaxilla and had the advantage of having no external scar. Lateral rhinotomy approach gave the widest access and exposure to all the regions, but with an external scar.

Nasal endoscopic excision had the advantage of tumour excision under direct vision and had no external scar. Hence it could be used as adjuvant for other approaches especially when the tumour is extensive and had to be removed piecemeal. It is also useful to assess the surgical cavity for bleeding and tumour remnants after the excision of the tumour by any approach. But it has the disadvantage of piecemeal removal, risk of recurrence and excessive time consumption for the procedure especially if it is the sole approach employed for removal of the tumour. Hence it appeared to be more suitable for early tumors especially in the pediatric patients where radical surgeries were not advisable<sup>33</sup>.

The preferred management protocol for most recurrent cementifying fibromas involves conservative removal which attempts to preserve form and function of the affected site. Residual disease when unavoidable often remains quiescent for extended periods of time without causing any compromise to the patient.

#### RECONSTRUCTION FOLLOWING SURGERY<sup>35</sup>

Reconstruction of the defect can be done simply with primary closure. It has also been done with split thickness skin grafting, regional flap, Skin graft, tongue flap and buccal pad of fat. Studies suggested that the buccal fat of pad with its high vascularity and easy harvesting technique has a very high success rate in the reconstruction of oral defects. It has been used to close the palatal defect after excision of the cement-ossifying fibroma along with BIPP pack.

#### RADIOTHERAPY<sup>14,28,29,32</sup>

These lesions are insensitive to radiotherapy. Radiotherapy is considered ineffective and is in fact contra-indicated. Since it is radio-resistant and to avoid post-radiation complications, radiotherapy is avoided. Osteosarcoma has developed after bilateral mandibular sclerotic changes had been diagnosed radiologically as cementifying fibroma in a patient who had received radiation therapy (56 Gy) because of a high grade astrocytoma of the brain three and a half years earlier.

## RECURRENCES<sup>2,30</sup>

Recurrence has not been reported as a major issue by most workers and authors with respect to this diagnosis. Commonly these patients have been followed up for 1 to 2 year periods during which time no recurrent lesion has been documented. Recurrence has been reported in as many as 28% of patients with mandibular central cementoossifying fibromas. The recurrence rate of maxillary central cementoossifying fibromas is unknown, but it is likely to be higher because of the greater difficulty of their surgical removal and larger size at the time of presentation.

However recurrence has been reported in a case after 7 years.

## PROGNOSIS<sup>28</sup>

Overall, a fairly good prognosis has been reported for this lesion. However, relapse of COF is higher in case of maxillary COF compared to the mandibular ones due to greater difficulty during surgical removal and their larger size at the time of presentation. Also, in cases of unusually aggressive behavior of this lesion, morbidity may be related to radical procedures that are adopted to achieve clearance and cure.

## CONCLUSION:

This case of Cementifying Fibroma of Maxilla has been reported in view of the rarity of this condition. It is not a clinical picture that is commonly encountered in the ENT OPD; making the Histo-

Pathological Diagnosis even rarer. Considering the natural history of this condition, the best part is the completeness of management that is possible, giving utmost satisfaction to both the patient and the operating surgeon.

## References:

1. Rama Raju D. Cementifying Fibroma – A Case Report. Annals and Essences of Dentistry. Jan-Mar 2010; Vol 2; Issue 1.
2. Demetrio Tamiolakis et al. Cementoossifying fibroma of the Maxilla: A case report. Acta Stomatol Croat, Vol. 39, br. 3, 2005.
3. Taylor ND et al. Recurrent cementifying fibroma of the maxilla: report of case. J Oral Surg. 1977 Mar;35(3):204-8.
4. Mahnaz Sheikh et al. Central Cementifying Fibroma of the Maxilla. Dental Research Journal. January 2013; Vol 10; Issue 1:122-125.

5. Mounesh Kumar CD et al. Juvenile Aggressive Cementoossifying Fibroma Of Maxilla: A Case Report. J of International Dental and Medical Research. 2012;Vol 5 (2): 106-109.
6. B Bertrand MD et al. Juvenile Aggressive Cemento-ossifying Fibroma: Case Report and Review of the Literature. Laryngoscope 103. Dec 1993.
7. Kazuyoshi Ozawa. A case of peripheral cementifying fibroma of the mandible. Shigaku Odontology. June 1998, Volume 86, Issue 1, pp 202-208.
8. S Kristensen et al. Aggressive cementifying fibroma of the maxilla. Archives of otorhinolaryngology. April 1986, Volume 243, Issue 2, pp 102-105.
9. Suchetha A et al. A Case Report on Peripheral Cementifying Fibroma. JIADS. Jan-March 2011; Vol 2 (1):43-45
10. Charles A Waldron, DDS, MSD et al. Benign fibro-osseous lesions of the jaws: A clinical-radiologic-histologic review of sixty-five cases: Part II. Benign fibro-osseous lesions of periodontal ligament origin. Oral Surgery, Oral Medicine, Oral Pathology Volume 35, Issue 3, March 1973, Pages 340–350.
11. Michael S Hauser, DMD, MD et al. Bilateral ossifying fibroma of the maxillary sinus. Oral Surgery, Oral Medicine, Oral Pathology. Dec 1989; Vol 68(6):759-763.
12. Ivor R H Kramer et al. The WHO Histological Typing of Odontogenic Tumours. CANCER December 15, 1992, Volume 70, No. 12.
13. Shikha Choubey et al. Peripheral cementifying fibroma: a clinical diagnostic dilemma. BMJ Case Rep 2013. doi:10.1136/bcr-2013-009472
14. Dalghous A et al. Cemento-ossifying fibroma occurring in an elderly patient. A case report and a review of literature. Libyan J Med. 2007 Jun 1; 2(2):95-8.
15. Singhal A, Ram R, Singhal P, Bhatnagar S, Das U M. Cemento-ossifying fibroma of maxillary antrum in a young female patient. J Indian Soc Pedod Prev Dent 2011; 29:44-7.
16. James E Hamner III et al. Cemento-ossifying fibroma of the maxilla. Oral Surgery, Oral Medicine, Oral Pathology. Oct 1968; Vol 26; Issue 4:579-587.
17. A J Kuta et al. Central Cementoossifying Fibroma of the maxilla : review of six cases. AJNR 1995 16: 1282-1286.
18. L R Eversole et al. Ossifying fibroma : A clinicopathologic study of 64 cases. Oral Surgery, Oral Medicine, Oral Pathology. Nov 1985; Vol 60; Issue 5:505-511.

19. Soleman Abbas Khan et al. Ossifying fibroma of maxilla in a male child: Report of a case and review of the literature Natl J Maxillofac Surg. 2011 Jan-Jun; 2(1): 73–79.
20. Sumona Pal et al. The varying clinical presentations of peripheral ossifying fibroma: A report of three cases Rev OdontoCienc 2012;27(3):251-255.
21. AnirbanChaterjee et al. Peripheral cemento-ossifying fibroma of maxilla. J Indian Soc Periodontol. 2010 Jul-Sep; 14(3): 186–189.
22. L R Eversole et al. Radiographic characteristics of central ossifying fibroma. Oral Surgery, Oral Medicine, Oral Pathology. May 1985; Vol 59; Issue 5:522-527.
23. Sweet RM et al. Recurrent cementifying fibroma of the jaws. Laryngoscope. 1981 Jul;91(7):1137-44.
24. Gupta AK et al. Cementifying fibroma presenting with frontoethmoidal mucocoele. A case report. Otorinolaringologia 2003 June;53(2):71-4.
25. Piyush Verma et al. Cemento-Ossifying Fibroma of the Maxilla: A Case Report. Indian J Otolaryngol Head Neck Surg; July 2011;63(Suppl 1):S38-S40.
26. Ashish Yadav et al. Peripheral Cemento-ossifying Fibroma of the Mandible: A Case Report. Indian J Stomatol; 2011;2(3):193-96.
27. Sankaranarayanan S et al. "Hybrid" lesion of the maxilla. J Oral Maxillofac Pathol 2011;15:299-302.
28. Mithra R, Baskaran P, Sathyakumar M. Imaging in the Diagnosis of Cemento-Ossifying Fibroma: A Case Series. J Clin Imaging Sci 2012;2:52.
29. Aitasalo K et al. Proc Finn Dent Soc. 1990;86(3-4):149-55.
30. M. Imanimoghaddam DDS et al. Cemento-Ossifying Fibroma: Study of Radiographic Features of Six Cases. Iran J Radiol 2009, 6(4).
31. Khan SA, Sharma NK, Raj V, Sethi T. Ossifying fibroma of maxilla in a male child: Report of a case and review of the literature. Natl J Maxillofac Surg 2011;2:73-9.
32. Agarwal et al. Recurrent bimaxillary opacities. Contemporary Clinical Dentistry. April 2012; Vol 3 (1).
33. B.K. Vikram, S.G. Udayashankar: Sinonasal Ossifying Fibroma: A Study of Six Cases and Review of Literature. The Internet Journal of Otorhinolaryngology. 2006 Volume 4 Number 2. DOI: 10.5580/26e0.



34. Cubukcu CE, Sevinir B, Ozbek S, Akin S, Yalcinkaya U (2011) A Rare Case of Psammomatoid (Juvenile) Ossifying Fibroma of the Maxillary Sinus. Dentistry 1:109. doi:10.4172/2161-1122.1000110.

35. Sivaraj S, Jeevadhas P. Reconstruction of maxillary cemento-ossifying fibroma defect with buccal pad of fat . J Pharm Bioall Sci 2013;5:198-200.