University Journal of Surgery and Surgical Specialities

ISSN 2455-2860 2021, Vol. 7(4)

A Histological Surprise – Skin Adnexal Tumor

Srinivasan, Rajkumar, Thirumalaikannan, Saravanan, Latha , Maruthu Pandian
Department of General Surgery, Madurai Medical College.

ABSTRACT

Chondroid syringoma represents the cutaneous counterpart of mixed tumour {pleomorphic adenoma} of salivary gland. It is a small size skin adnexal tumour frequently on head and neck. It can be rarely malignant. Their clinical presentation is not specific & final diagnosis is based on HPE. But it can't reliably differentiate benign & malignant. Till now < 40 cases of malignancy reported world wide. We present a case of 33 year male with swelling in the left cheek just above the upper lip, which was clinically diagnosed as neuroma, but histopathology suggested the diagnosis of chondroid syringoma. This case is being presented for its rarity.

Keywords

Skin Adnexal Tumor, Chondroid Syringoma , Sweat Gland Tumor**.**

INTRODUCTION

Surprisingly, Theodor, father of modern abdominal surgery was the one who first described this tumor in 1859 as " an entity having same histology like that of mixed tumor of salivary gland. In 1961 Hirsch & Helwig contribute the term " Chondroid Syringoma " {after reviewing 188 casesof mixed tumors of skin} - which has been retained in histologic typing of skin tumors of WHO[{1}].

It is a rare sweat gland tumor which derived from epithelial & mesenchymal cells with glands of apocrine and eccrine type[{1}]. It constitutes 0.01% to 0.1% of all primary skin tumors[{1}]. These are usually solitary and most commonly in age >35 yrs. M:F – 2:1 – 5:1. Here we present a case of swelling in the left cheek just above the upper lip which was clinically diagnosed as neuroma, but histopathology suggested the diagnosis of chondroid syringoma. This case is being presented for its rarity.

CASE REPORT

A 33 year old male presented with Swelling in the left cheek just above the upper lip for 1 month which was Insidious in onset, Slowly progressive with no influencing factors. No H/O of pain / ulcer / fever/ excess salivation.

Clinical feature: A single swelling of 2*1 cms in size above and lateral to left commissure obliterating the left nasolabial fold with extension upto the buccal mucosa. Skin over the swelling can be moved and found to be normal. No cervical lymphadenopathy. Oral cavity examination was otherwise normal.

USG local part:

A well defined 3*3 cms soft tissue swelling in subcutaneous plane.

No regional lymph nodes.

FNAC:

BENIGN ADNEXAL TUMOR

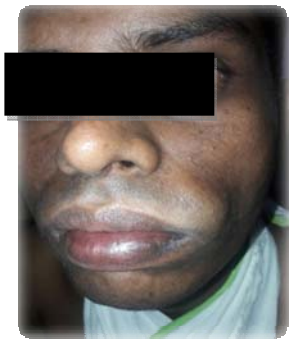

Fig 1: swelling in the left cheek

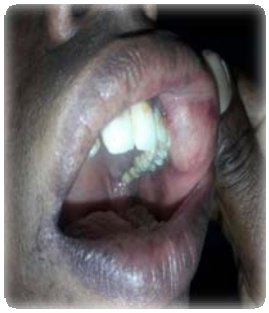

Fig 2: intra oral view

PROCEDURE DONE : Excision biopsy under GA

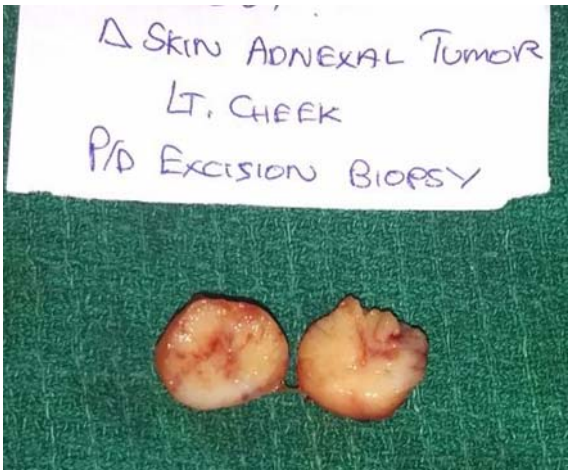

Fig 3: Gross specimen

POST OP HPE :

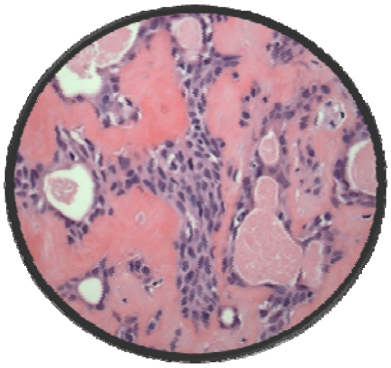

Fig 4: high-power (100×) views show biphasic population of tumor cells [cuboidal and polygonal] arranged in a ductal spaces with an amorphous esoinophilic material with in their

CONCLUSION

Chondroid syringoma also known as pleomorphic adenoma of the skin, the term given by Hirsch and Helwig is a rare sweat gland tumor. Histologically, mixed tumors of skin are two types, one with tubular and cystic with partially branching lamina {Apocrine} & with small regular tubular lamina {eccrine}[2]. Hirsch and Helwig gave five histopathological criteria for diagnosis: 1. Nests of cuboidal or polygonal cells; 2.Intercommunicating tubule-alveolar structures lined by two or more rows of cuboidal cells; 3.ductal structures composed of one or two rows of cuboidal cells; 4.Occasional keratinous cysts; 5. A matrix of varying composition. Chondroid syringoma may have all 5 features or only some[3]. In our case, 2 out of 5 criteria were present. The exact etio-pathogenesis is unknown, but there is hypothesis about its both epithelial and mesenchymal origin[4]. Some suggest its origin from both secretory and ductal components of sweat glands[5]. Chondroid syringoma is usually seen in middle aged male patients[6].

These are mostly benign entities that usually present asymptomatically in middle-aged men with a predilection for the head and neck region[7]. The gross appearance is typically described as a slow-growing, solitary, non ulcerating mass ranging in size from 0.5 to 3.0 cm.5 However, cases of benign chondroid syringoma larger than 3.0 cm have been reported. Tumors larger than 3.0 cm are associated with a greater likelihood of malignancy[8] As of now, < 50 cases of malignant chondroid syringoma have been described[9] Malignancy is more common in females, with no age predilection, and are observed more commonly on the extremities. Malignant chondroid syringoma typically arise de novo and not from a preexisting benign chondroid syringoma[8].

Histologic features that suggest malignancy include cytologic atypia, tumor necrosis, numerous mitoses, excessive mucoid matrix, and poorly differentiated chondroid components[9]. The differential diagnosis of chondroid syringoma includes benign tumors of epidermal or mesenchymal appendages such as dermoid or sebaceous cyst, neurofibroma, dermatofibroma, basal cell carcinoma, pilomatricoma, histiocytoma, and seborrheic keratosis[11]. The lesions of chondroid syringoma usually are not clinically distinctive and the diagnosis is made on microscopic examination of tissue obtained by excisional biopsy**(12)**. However, if presentation is questionable, a fine-needle aspiration may be of value since chondroid syringoma has been distinguished using this technique[10]. Fine-needle aspiration has its limitations, such as sampling errors for histologic analysis that will require an experienced cytologist[10]. The definitive approach for diagnosis and treatment is excisional biopsy. The surgeon needs to ensure that the margins are free of tumor. Regular follow-up is recommended to evaluate for recurrence following tumor excision, especially in the absence of negative margins[10]. Epithelial cells are CEA & cytokeratin positive. Myoepithelial cells are vimentin & S100 positive. Review of the literature has shown a paucity of information regarding long-term follow-up after excision and recurrences. There is no known recurrence reported after complete excision of the lesion, with a short-term follow-up of 2 years[10]. In our case, it was diagnosed clinically as neuroma, but HPE was in favour of chondroid syringoma. The treatment of benign tumor is complete surgical excision. Because of rare possibility of malignancy, it is important to include a margin of normal tissue with the excision to ensure complete removal of the tumor [13] .

DISCUSSION

Chondroid Syringoma may be confused clinically with epidermal cyst, pilar cyst, calcifying epithelioma or a solitary trichoepithelioma which is probably the reason for the tumor not being sent for HPE after excision earlier. Recurrence of the lesion alerts the clinician to the possibility of malignancy. Histopathology is the only mode of diagnosis. But still, it is not very reliable to distinguish benign and malignant. Excision is the treatment of choice with regular follow up in view of local recurrence or metastasis.

INFORMED CONSENT : Obtained consent for photographs.

CONFLICT OF INTEREST: No conflict of interest was declared by authors

FINANCIAL DISCLOSURE : The authors declared that this case has received no financial support.

REFERENCES

1. Yavuzer R, Bas¸terzi Y, Sari A, Bir F, Sezer C. Chondroid syringoma: a diagnosis more frequent than expected. Dermatol Surg. 2003;29(2):179-81.

2. Hirsch P, Helwig EB. Chondroid syringoma: mixed tumor of skin, salivary gland type. Arch Dermatol. 1961;84(5):835-47.

3. Hirsch P, Helwig EB. Chondroid syringoma. Mixed tumor of skin, salivary gland type. Arch Dermatol, 1961; 84: 835-47.

4. Borman H, Ozcan G. Chondroid syringoma at the fingertip: an unusual localization. Eur J Plast Surg, 1998; 21(6): 311-3.

5. Bates AW, Baithun SI. Atypical Mixed Tumor of the Skin: histologic, immunohistochemical, and ultrastructural features in three cases and a review of the criteria for malignancy. AmJ of Dermatopathol, 1998; 20(1): 35- 40.

6. Yuvuzer R, Basterzi Y, Sari A, Bir F, Sezer C. Chondroid syringoma: a diagnosis more frequent than expected. Dermatol Surg, 2003; 29(2): 179-81.

7. Chen AH, Moreano EH, Houston B, Funk FG. Chondroid syringoma of the head and neck: clinical management and literature review. Ear Nose Throat J. 1996;75:104-8.

8. Sungur N, Uysal A, Gumus M, Kocer U. An unusual chondroid syringoma. Dermatol Surg. 2003;29 (9):977-9.

9. Saxena A, Kamath N,Malik R. A rare case of malignant chondroid syringoma of scalp. Indian Dermatol Online J. 2013;4(3):236-8.

10. Skoro M, Ostovic KT, Cikara I, Muller D, Novak NP, Virag M. Fine needle aspiration cytology of chondroid syringoma. Coll Antropol. 2010;34(2): 687-90.

11. Poku JW, Sant GR, Ucci AA. Chondroid syringoma of the scrotum. J Int Med Res, 1997; 24(6): 482-6.

12. Miracco C, De Santi MM, Lalinga A. Lipomatous mixed tumour of the skin: a histological, immunohistochemical and ultrastructural study. Br J of Dermatol, 2002; 146(5): 899-903

13. Barnett MD, Wallack MK, Zuretti A, et al. Recurrent malignant chondroid syrinoma of the foot: A case report and review of literature.Am J Clin Oncol.2000;23(3):227-32.