University Journal of Surgery and Surgical Specialties

ISSN 2455-2860 Volume 2 Issue 6 2016

Giant Hepatic Hemangioma Managed with Resection through a combination of median sternotomy and laparotomy , after attempted Angioembolisation and sorafenib therapy.- A Case report.

GNANASEKAR M MURUGAIYAN
Department of Surgical Gastroenterology and Proctology,
MADRAS MEDICAL COLLEGE AND GOVERNMENT GENERAL HOSPITAL

Abstract :
Abstract Giant Symptomatic Hepatic Hemangioma, demanding surgical intervention can pose problems owing to their large size . Here we report a case of Giant hepatic Hemangioma of size 37x19x 15 cm in a 34 year old female ,who remained symptomatic for 6 months .Since the hemangioma was actually growing and she complained of increasing abdominal and respiratory symptoms, we decided to intervene. First we performed transcatheter arterial embolization(TAE) of the hepatic arteries,which failed to cause regression of the size and her symptoms. As a next measure, we started sorafenib ,based on a similar such case report in Japan.The tumor shrunk with symptomatic improvement. But unfortunately the drug could not be continued because of the intolerable side effects, which terminated in stoppage of the drug..With her symptoms worsening , we planned for surgical resection. Surgery was done along with Thoracic surgeons ,wherein we employed a median sternotomy and Makucchi incision. Intrapericardial IVC was accessed and kept ready for possible venovenous bypass if necessity arises. Inflow achieved with intermittent pringles maneouvre. Complete resection of the lesion was done.
Keyword : Hemangioma, Transcatheter arterial embolization, Sorafenib ,Makucchi. pringle maneovre

Background:
Hepatic hemangiomas need to be treated surgically in cases where they are accompanied with symptoms, have a risk of rupture, or are hardly distinguishable from malignancy. Liver hemangiomas are the most common benign tumors occurring in the liver, and are believed to be slowly growing hamartomatous lesions or true vascular neoplasms]. They occur more frequently in women than in men, and are believed to be related to levels of female

hormones because their size increases during pregnancy]. In most cases, the hemangioma is small in size and asymptomatic, and thus follow-up is considered enough, without treatment. However, a giant hemangioma, which is defined as a hemangioma over 4 cm in diameter, can cause symptoms and require intervention. Preoperative diagnosis is possible using ultrasound or helical CT. Here, we report the successful removal of a giant hemangioma (over 30 cm) from the right side of the liver through a thoracoabdominal approach , after transarterial embolization (TAE), and a trial of Sorafenib therapy.

Case Report:.

Here we report a case of giant hemangima of size 37x19x 15 cm occupying the entire Rt lobe of the liver in a 30 year old woman ,who presented initially with abdominal and respiratory discomfort ,with in creasing abdominal distension , owing to the huge size of the lesion.

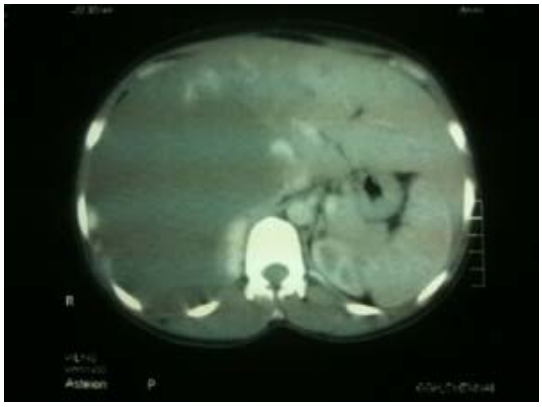

CECT-Abdomen

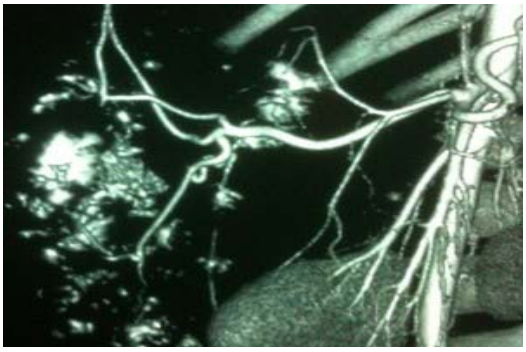

CT -Angiogram

Stage 1

With this huge size , we decided to manage it stage wise ,initially trying it with angioembolisation radiologically. (Transfemoral approach Seldinger's technique). We performed abdominal angiography followed by transcatheter arterial embolization (TAE). That is, 2 mg of contrast agent mixed suspension gelatin particles was injected from Rt hepatic artery .Though the procedure was a technically successful one , tumour regression in terms of size and symptoms were not appreciated significantly.

Angioembolisation

Stage 2

Literature review revealed , a similar such lesion managed with Sorafenib , a multiple tyrosine kinase inhibitor (14)**.** With this literature support we started the drug therapy , after documenting the preinduction size of the tumour by means of USG and followed it up with same radiologist ,weekly. Sorafenib therapy:

Volume of the lesion at the time of Induction of the drug: 4799cm3 After day 6: 3656cm3, After 1 month 2673 cm3, **55.6 % REDUCTION.IN GROSS SIZE** We could demonstrate a appreciable reduction in size of the lesion ,with the drug.but unfortunately it could not be continued because of the drug intolerance.

Side effects experienced:
Intractable Hypertension,Skin rashes,GI upset,Respiratory distress.. The side effects, necessitated holding up of the drug thrice and finally drug was withdrawn .

Stage3
With her symptoms increasing , we planned for Rt. Hepatectomy. Because of the tumour 's huge size, we planned a combined thoracic and abdominal approach .Abdomen and thorax was accessed with Makucchi and median sternotomy. supra-hepatic ,intrapericardial IVC control was achieved by the thoracic team(fig7,8) . Inflow control with intermittent pringles maneovre,and infrahepatic suprarenal IVC was mobilized before proceeding on with liver mobilisation . Rt. Lobe was mobilized by incising the ligaments and the lobe was separated from the retrohepatic IVC by clipping the veins . It took 7 hrs to complete the entire surgery with 14 units of transfusion of whole blood peroperatively .The tumour weighed 5200mg, post operatively pt resumed oral diet on her third day after an initial inotropic support and elective post op ventilation on her first post operative day.

median sternotomy

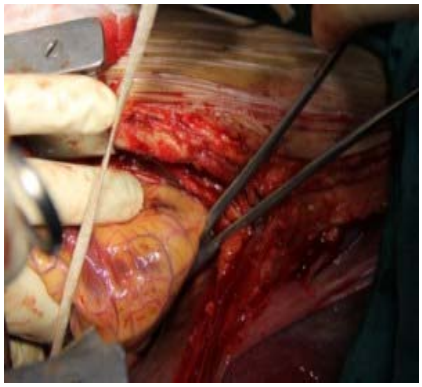

Getting hold of Intrapericardial IVC

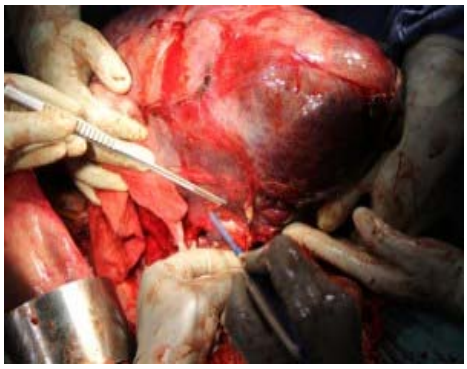

Getting separated from IVC

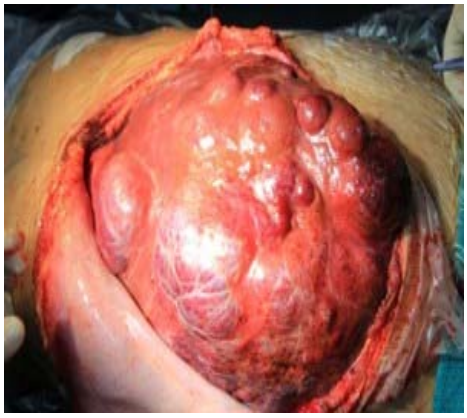

INCISION-MAKKUCCHI

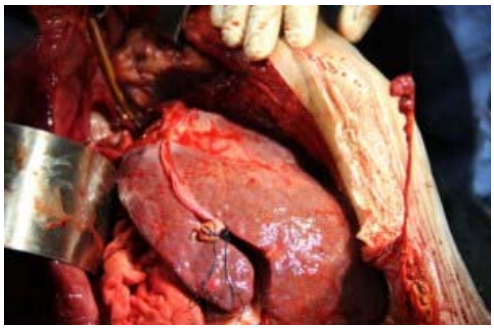

Remnant liver before closure

Discussion :

Hemangioma represents a congenital, non-neoplastic hamartomatous proliferation of vascular endothelial cells,which originates from mesodermal layer. Its etiology remains unclear . Around 80% of the hemangiomas affect the skin(1), with the liver being the internal organ that is most likely to get affected. In 2400 autopsies reviewed by Oschsner the incidence was found to be 2%(10)They are more common in the right lobe of the liver than in the left lobe(2))The incidence of cavernous hemangiomas has been documented to be as high as 7 percent in one autopsy series .majority being found incidentally upon routine imaging.

Macroscopically it appears as a well-circumscribed, hypervascular and compressible lesions with a clear sheath of compressed liver parenchyma between haemangiomatous tissue and normal liver. microscopically it appears as.ectatic blood filled spaces, lined with vascular endothelium and separated by fibrous septa with a variable sclerotic componentliver. Histological variants are Fibrolamellar interface, Interdigiting pattern, Compression interface,Spongy interface. The lesion is predominantly found in female, about 4.5 times higher than the male(11),Prompting some researchers to suggest that sex hormones are somehow involved in stimulating growth and producing symptoms, sex-dependent differences in penetrance , the expression of a presumed liver-hemangioma gene, or the production of proliferative factors, such as female sex hormones(9). endogenous and exogenous female sex hormones seem to play a role in the pathogenesis of liver haemangiomas although significant enlargement occurs in only a minority of patients. (12). Only haemangiomas greater than 5 cm may cause symptoms. Prolonged clinical and sonographic follow up of small and medium sized haemangiomas is not warranted (7). The majority of evidence indicates that the natural history of liver haemangioma is uncomplicated and most lesions are asymptomatic. There is a positive correlation between the tumour size and its symptoms with well over 90% of the patients becoming symptomatic once it reaches a size of over 10 cm (8). Mostly the symptoms arises due to rapid expansion of the tumor or to thrombosis and infarction that result in stretching or inflammation of Glisson ’s capsule,producing pain .other symptoms are Biliary colic, Torsion of a pedunculated lesion, Gastric obstruction, pulmonary embolism, Spontaneous rupture with intraperitoneal hemorrhage. Rarely can a hemangioma present with Intratumoural bleeding,Spontaneous rupture and hemoperitoneum,And still more rarely Kassabach meritt syndrome , characterised by thrombocytopenia and consumptive coagulopathy. The mortality rate in this condition approaches 30%, thereby necessiating prompt intervention. .The diagnostic specificity--U/S 60.3%, CT scanning 55.0%, MRI 85.7%(13).Even though MRI is considered to be the most sensitive and the most specific diagnostic study, with its . T2weighted image demonstrating a characteristic hyperintense pattern, it is

the CECT in most cases ,with its Irregular peripheral nodular enhancement (initial injection of contrast) , central filling of the hypodense lesion; that persists for some time (several minutes after contrast) ,that makes the diagnosis certain in most cases. . Besides the typical ones which we encounter routinely there are instances where one could possibly see atypical ones too such as Large, heterogeneous hemangiomas; Rapidly filling hemangiomas, Calcified hemangiomas, Hyalinized hemangiomas,Cystic or multilocular hemangiomas , Pedunculated hemangiomas.,wherein Diffusion weighted MRI ,has got a role in differentiating theses lesions from other SOL.(3) Management of hemangioma liver In most instances is observation ,irrespective of the size if it is going to be asymptomatic.Besides the relative indications such as Persistent abdominal pain, obstructive jaundice, portal hypertension, superficial location of tumors larger than five cm with a risk of trauma, and an uncertain diagnosis ,there are absolute indications such as spontaneous or traumatic rupture with hemoperitoneum, intratumoral bleeding, consumptive coagulopathy (Kasabach-Merritt syndrome.(5) (6) ,Other than these indications management in most instances Is observation . surgery remains the only consistently effective curative treatment for giant haemangioma and should be considered for patients with complicated or symptomatic lesions, where operative risk is acceptable.w Ligation of hepatic artery, Selective transcatheter arterial embolization, Radiation therapy ,Radiofrequency ablation.There are instances where liver transplantation too has been offered for patients presenting with complications. (4)

Inference.:

Here in this case , we adopted a rather step wise approach in managing this large tumour,initially trying to manage with angioembolisation, and then with Sorafenib therapy, both of them were not much helpful. With surgery , particularly ,the thoracoabdominal approach,employing median sternotomy, reduced the technical difficulty in gaining control over the outflow tract.,particularly in a tumour of this mammoth proportion which stretched the Rt. Dome of diaphragm, thus leaving the operating surgeon,enough space to gain adequate outflow control . This combined approach (thoracoabdominal)has been reported as a useful method for right side hepatectomy by Japanese and European researchers since the 1990s. Compared to conventional approaches, the thoracoabdominal approach is just as safe as a right-sided hepatectomy, but it seems not to be used frequently because the chest has to be opened and an intra-thoracic drainage tube has to be inserted. We would like to insist that the intra-thoracic drainage tube, did not cause much intercostal pain or neurogenic pain In addition, the intra-thoracic drainage tube was removed early; therefore it did not affect the postoperative course. The thoracoabdominal approach is obviously a useful method for the safe resection of the right triangular ligament and mobilization of the right liver from the inferior vena cava. Accordingly, when a right-side hepatectomy is performed for a huge mass, such as a giant hemangioma in the right liver, a median sternotomy incision using a thoracoabdominal approach is considered a safe and useful method.

References:

1. Rosai. Ackermann’s., Surgical Pathology,9/e(Vol2))

2 David C Wolf, MD, FACP, FACG, AGAF – Unnithan V Raghuraman, MD, FCRP, FACG, FACP Hemangioma, Hepatic: emedecine < Gastroenterology < Liver, Dec 22, 2008))

3 Jang HJ, Kim TK, Lim HK, et al. Hepatic hemangioma: atypical appearances on CT, MR imaging, and sonography. AJR Am J Roentgenol. 2003;180:135–141. [PubMed]

4 Hochwald SN, Blungart LH. Giant hemangiomas withKasabach-Merritt syndrome: Is the appropriate treatment enu-cleation or liver transplantation? HPB Surg 2000;11:413–419)

5 Pietrabissa A, Giulianotti P, Campatelli A, Di Candio G, Farina F, Signori S, et al. Management and follow-up of 78 giant hemangiomas of the liver. Br J Surg. 1996;83:915–8. [PubMed]

6 Moreno AE, Del Pozo MR, Vicente MC, Abellan JA. Indications for surgery in the treatment of hepatic hemangioma. Hepatogastroenterology. 1996;43:422–6. [PubMed],

7 Gandolfi L , Leo P, Solmi L, et al. A. Natural history of hepatic hemangiomas: clinical and ultrasound study, Gut 1991;32:677–80. [PMC free article] [PubMed]).

8 Goodman Z. Benign tumors of the liver. In: Okuda K, Ishak K G. Neoplasms of the liver. Tokyo: Springer-Verlag; 1987:105-125.)

9 K G and Rabin L: Benign tumors of the liver. Med. Clinic N America 1975; 59:995-1013).

10 Oschsner J L and Halpert B: cavernous hemangioma of the liver. Surgery 1958; 43:577-582;

11 Schumacker H B and Baltimore: Hemangioma of the liver. Surgery 1942; 42:209-220),

12 Hepatic haemangiomas: possible association with female sex hormonesV Glinkova, O Shevah, [...], and H Shirin

13 .Diagnosis of liver hemangioma. [Article in Bulgarian, English]Taseva A1, Tasev V2, Bulanov D2, Dimitrov K2, Popov V2, Zivkov E2, Dimitrova V2

14 Giant cavernous hepatic hemangioma shrunk by use of sorafenib-Satoyoshi Yamashita, Kohsuke Okita, Katsunori Harada, Atsuyoshi Hirano, Teruaki Kimura, Akira Kato, Kiwamu Okita)