



RARE CASE OF PRIMARY MULTI DRUG RESISTANCE TUBERCULOSIS WITH HUMAN IMMUNODEFICIENCY VIRUS INFECTION AND TRACHEOESOPHAGEAL FISTULA MAHESWARAN K

Department of Tuberculosis Respiratory Disease, STANLEY MEDICAL COLLEGE AND HOSPITAL

Abstract : In 2012, one fourth of the TB cases reported globally occurred in India. Complications due to tuberculosis have increased due to immunodeficiency. Tracheoesophageal fistula is a rare complication of tuberculosis, presenting with recurrent respiratory tract infection and cough while swallowing liquids. Most common reason for fistula could be due to rupture of the caseonecrotic mediastinal lymph node. We are reporting an immunodeficient patient with tracheoesophageal fistula due to tuberculosis. Sputum line probe assay was sent to intermediate research laboratory (IRL Chennai) to assess drug resistance pattern, which showed resistance to rifampicin and sensitive to isoniazid. Patient was diagnosed to have primary multidrug resistance TB as there was no previous history of anti-tuberculous treatment. Tracheoesophageal fistula was managed conservatively with PEG (Percutaneous endoscopic gastrostomy) because of active infection.

Keyword : Tracheoesophageal fistula, Multi Drug Resistance, Percutaneous endoscopic gastrostomy

INTRODUCTION : Tracheoesophageal fistulas resulting from Mycobacterium tuberculosis infection is uncommon; however, its incidence appears to be rising in immunocompromised host. Tracheoesophageal fistulas are divided into congenital and acquired. The latter is rare and can occur as a secondary to malignancy, trauma, surgery, contagious diseases such tuberculosis, candidiasis, syphilis. Among infectious causes tuberculosis is the most common etiology. The most frequent sign of TEF is coughing after swallowing. The diagnostic evaluation is by bronchoscopy and esophagoscopy. After diagnosing, the immediate goal is to minimize tracheobronchial soilage.

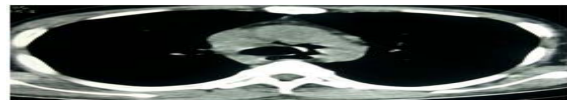
CASE REPORT:

A 34 years old male patient presented with cough with sputum production, breathlessness for past 1 month. On evaluation, Patient sputum smear for Acid Fast Bacilli found to be positive and blood for HIV tridot positive. According to MDR suspect criteria (criteria C) patient sputum sample was subjected to line probe assay and was reported as isoniazid sensitive and rifampicin resistant, was started on CAT -IV ATT regimen according to his body weight (35 kg). (inj. Kanamycin 500 mg, tab. Levofloxacin 750mg, tab. Pyrizinamide 1250mg, tab. Ethambutol 800mg, tab. Ethionamide 500mg, tab. Cycloserine 500mg, pyridoxine 100mg) after 2 weeks of CAT- IV ATT, Anti-Retroviral therapy was started (zidovudine 300mg/bid, lamivudine 150mg/bid, and

efavirenz 600mg/od). After 1 month of treatment patient developed new symptoms, cough while drinking water as well as swallowing food and increased breathlessness. On examination patient was thin built, auscultation revealed fine mid and late inspiratory crackles in right mammary area. Chest X Ray showed new opacity in right lower zone, pneumomediastinum. So CT chest was taken which revealed communication between the trachea and the esophagus, with pneumomediastinum and mediastinal adenopathy, probably rupture of caseonecrotic mediastinal node produces the communication between trachea and esophagus. Hence patient was diagnosed as tracheoesophageal fistula.



chest x ray- pneumomediastinum



ct chest - communication between trachea and esophagus

Patient was temporarily managed with Percutaneous Endoscopic Gastrostomy because of active infection. PEG tube placement helps in healing by favoring mucosal repair, preventing gastro esophageal reflux. CAT IV regimen and anti retroviral therapy was administered through Percutaneous endoscopic gastrostomy.

DISCUSSION:

Tracheoesophageal fistula is a rare complication in TB, but appears to be increasing especially in immunocompromised patients. Mycobacterium tuberculosis is most common infective etiology for tracheoesophageal fistula, and its management poses a challenge to the clinician. The pathogenesis of tracheoesophageal fistula may be due to (1) rupture of the caseonecrotic subcarinal lymph nodes into the trachea and the esophagus; (2) erosion of primary tracheal ulcer into the esophagus; (3) development of traction diverticula between the respiratory tree and esophagus. Tracheoesophageal fistula patients will have recurrent respiratory tract infection and cough following ingestion of liquid. Sometimes patient may present with fever, hemoptysis and dysphagia. Ono's sign refers to uncontrolled coughing on ingestion of liquids, and on auscultation, crepitation's are heard posteriorly over the upper interscapular

area which is pathognomonic of tracheoesophageal fistula. X-ray chest will show signs of aspiration pneumonia and lymph node enlargement. Bronchoscopy will help to locate the exact site of the fistula. Tuberculous tracheoesophageal fistula was treated previously by surgery. Nowadays management of fistula is mainly conservative with antituberculous therapy and Nasogastric tube placement or PEG (Percutaneous endoscopic gastrostomy) tube. Deverbhavi et al managed four cases of tracheoesophageal fistula with medical treatment alone and showed healing of fistula. Joanna porter managed three cases of tracheoesophageal fistula with immunodeficiency with antituberculous therapy and Nasogastric tube. Nasogastric tube has been used to permit healing of fistula. However, PEG tube placement is preferable as it prevents physical contact of catheter with the fistula. PEG tube placement helps in healing by favoring mucous repair, preventing gastro esophageal reflux and colonization along the Nasogastric tube. Surgical repair of fistula is required for large fistulas complicated by recurrent pneumonia. Injection of histocryl can be tried to close the fistula. Surgical management of acquired tuberculous tracheoesophageal fistula may be radical surgery or palliative surgery. Radical surgery consists of combination of pneumonectomy or pericardial patching of fistula with esophagectomy and restoration of gastrointestinal continuity using the stomach.

Bibliography:

1. Spalding AR, Burney DP, Richie RE. Acquired benign bronchoesophageal fistulas in the adult. *Ann Thorac Surg* 1979;28:379-83
2. Shah CP, Yeolekar ME, Pardiwala FK. Acquired tracheo-oesophageal fistula. *J Postgrad Med* 1994;40:83-4
3. Bashi SA, Laajam MB, Johariy IA, Abdullah AK. Tuberculous oesophagopulmonary communication: Effectiveness of antituberculous chemotherapy. A case report and review of literature. *Digestion* 1985;32:145-8
4. Braimbridge MV, Keith HI. Oesophago-bronchial fistula in the adult. *Thorax* 1965;20:226-33
5. Wigley FM, Murray HW, Mann RB, Saba GP, Kashima H, Mann JJ. Unusual manifestation of tuberculosis: TE fistula. *Am J Med* 1976;60:310-4
6. Devarbhavi HC, Alvares JF, Radhikadevi M. Esophageal tuberculosis associated with esophagotracheal or esophagomediastinal fistula: Report of 10 cases. *Gastrointest Endosc* 2003;57:588-92.
7. Porter JC, Friedland JS, Freedman AR. Tuberculous bronchoesophageal fistulae in patients infected with the human immunodeficiency virus: Three case reports and review. *Clin Infect Dis* 1994;19:954-7

