University Journal of Medicine and Medical Specialities

ISSN 2455- 2852 2018, Vol. 4(1)

LOEYS-DIETZ SYNDROME- A CASE REPORT

ARUN MATHAI MANI
Department of General Medicine,
MADURAI MEDICAL COLLEGE AND HOSPITAL.

Abstract :

We report here, the case of a 13 year old boy who was admitted with features of mitral valve prolapse, bifid uvula and marfanoid features. Further evaluation revealed him to be a case of Loeys-Dietz Syndrome (LDS), a very rare heritable disorder of connective tissue. He was treated symptomatically and was discharged in reasonable good health.

Keyword :"Loeys-Dietz Syndrome","Bifid uvula","Ocular hypertelorism","Arterial tortuosity"

Introduction:

Loeys-Dietz syndrome (LDS) is a genetic disorder that affects the connective tissue in the body. The disorder was first observed and described by Dr. Bart Loeys and Dr. Hal Dietz at the Johns Hopkins University School of Medicine in 2005.

The exact prevalence of LDS is unknown. There are approximately 300 – 400 patients worldwide. Individuals with LDS exhibit a variety of medical features in the musculoskeletal, skin and cardiovascular systems. Information about the natural history and management of individuals with LDS continues to evolve.

Case Report:

A 13 year old boy (Fig.1) was brought to our hospital with complaints of exertional shortness of breath and chest pain.

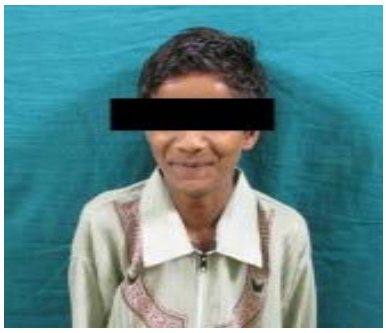

Figure 1. The case

He was born out of a second degree consanguineous marriage and there were no peri-partum complications. His developmental milestones were normal and scholastic performance was average. His father, mother and younger brother were apparently normal.

On examination, his built was asthenic with BMI of 12.65. There was no pallor, icterus, cyanosis, clubbing, oedema or lymphadenopathy. Pulse rate was 80 bpm, regular, large volume and noncollapsing. Blood Pressure was 100/70 mm Hg in right upper limb supine position.

Head to foot examination showed the following abnormalities:-

Skull: dolichocephalous, frontal bossing, retrognathia

Eyes: ocular hypertelorism (Fig.2), divergent squint

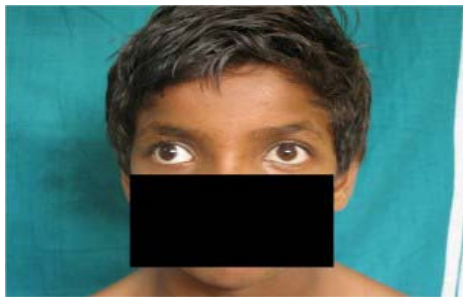

Figure 2. Ocular hypertelorism

Nose: depressed nasal bridge

Oral cavity: bifid uvula (Fig.3), high arched palate, superneumery teeth

Figure 3. Bifid uvula

Arms: arachnodactyly, camptodactyly (Fig.4), Steinberg/thumb sign (Fig.5), Walker–Murdoch/wrist sign(Fig.6)

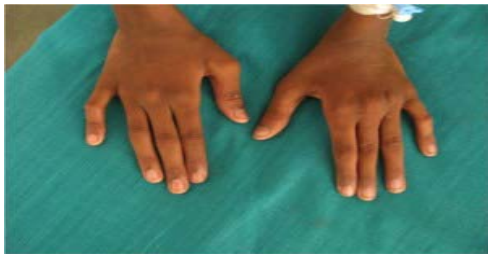

Figure 4. Arachnodactyly and camptodactyly

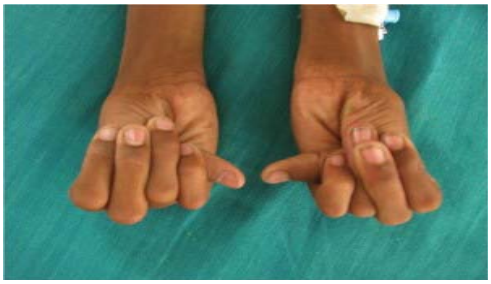

Figure 5. Thumb sign

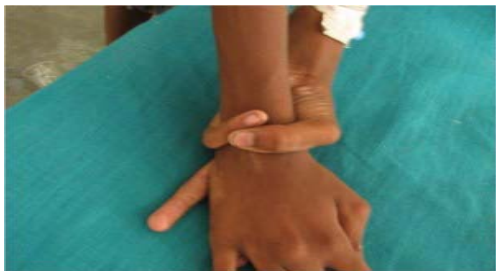

Figure 6. Wrist Sign

Chest: pectus carinatum
Spine: thoracic kyphosis
Lower limbs: genu valgum
Feet: pes planus
Joints: hypermobile with a Beighton Score 4/9
His height was 154cm, arm span was 158cm and ratio of upper segment to lower segment was 0.75.
Examination of his cardiovascular system showed hyperdynamic apical impulse with apical systolic thrill. On auscultation there were multiple mid systolic clicks followed by a high pitched late systolic crescendo-decrescendo murmur at the apex.
His respiratory system and abdominal examination were normal.
His IQ was 90 with average intellectual capacity.
Visual acuity of right eye was 1/60 and of his left eye was 6/6. Lens was normal with no subluxation
and there was no myopia.
Investigations:
Complete hemogram
Hb 10 gm/dL
PCV 30%
Tc 8100
Dc P59 L36 E2 M3
RBC 3.15 lakhs
PLC 5 lakhs
ESR 10
BT 2 min CT 4 min 30 sec
P/S – RBCs shows hypochromic microcytic and normocytic normochromic, WBC count is normal,
Platelets are normal in number and morphology
IMP – Dimorphic Anemia
RBS 120 mg/dl
Bl Urea 28 mg/dl Se Creatinine 0.7mg/dl
Na+ 140 K+ 4.3 Cl- 113 Ca 6.8 PO 5.3
ECHO: Mitral valve prolapse, both AML and PML are thick and prolapsing
MR Grade 2, AR Grade 1
Aortic root annulus 3.30 cm, sinus level 3.6 cm, Ascending aorta 3.4 cm
Chest X-ray: Cardiomegaly (CTR 62%) with LV configuration
X-ray both hands: diffuse osteopenia, Metacarpal Index increased suggestive of arachnodactly
X-ray both knees: genu valgum deformity
X-ray cervical spine in flexion and extension – no evidence of cervical spine instability
Carotid and Vertebral Artery Doppler: **Bilateral Common Carotids appears ectatic and tortuous.**
Bilateral Vertebral arteries appear ectatic and tortuous.
Bilateral external and internal carotids are normal
CECT Chest: Cardiomegaly with biventricular and left atrial chamber enlargement.**Dilated aortic root (Fig.7)** measuring 4.0 cm in diameter. Rest of ascending aorta, arch and descending aorta are normal. **Dilated main pulmonary artery and its root (Fig 8 and 9)** measure 3.0 cm and 4.0 cm in diameter respectively.

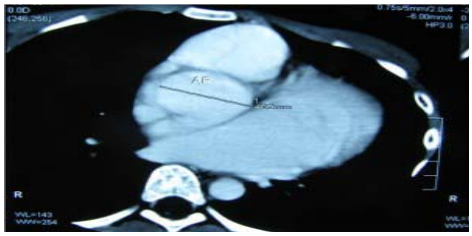

Figure 7. CECT showing dilated aortic root

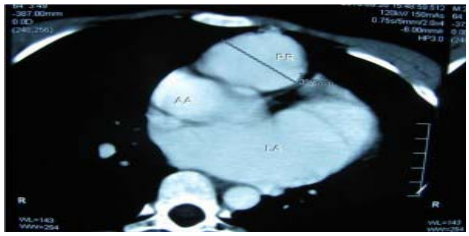

Figure 8. CECT showing dilated root of pulmonary Artery

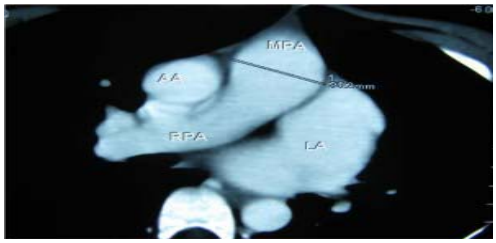

Figure 9. CECT showing dilated main pulmonary artery

MR Arteriography Of Neck Vessels: **Bilateral tortuosity with loop formation in vertebral arteries and internal carotid arteries (Fig 10 and 11)**. Both common carotid arteries appear normal.

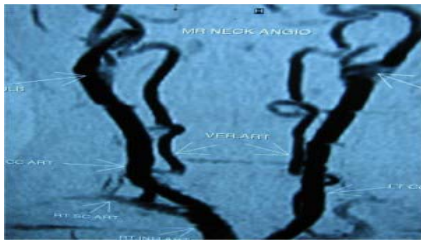

Figure 10. MRA neck showing arterial tortuosity

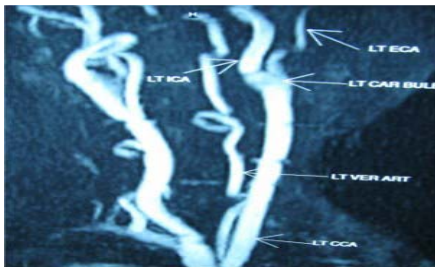

Figure 11.MRA neck showing arterial tortuosity

These investigations revealed that we are dealing with a 13 year old boy who has marfanoid habitus, arterial tortuosity, aortic root dilation and mitral valve prolapse.

The differential diagnoses that would prop up in this setting would be Marfan Syndrome (MFS), Shprintzen-Goldberg syndrome (SGS) and Loeys-Dietz syndrome (LDS).

The absence of ectopia lentis, dolichostenomelia and intellectual disability helped us to narrow the diagnosis in favour of Loeys-Dietz Syndrome.

Discussion:

Loeys-Dietz syndrome (LDS) is a genetic disorder that is caused by a mutation in either the TGFBR1 or TGFBR2 genes (transforming growth factor beta receptor 1 or 2). LDS is inherited in an autosomal
dominant manner. Approximately 25% of individuals diagnosed with LDS have an affected parent; approximately 75% have LDS as the result of a de novo gene mutation.

Prevalence

The prevalence of LDS is unknown. No apparent enrichment in any ethnic or racial group and no gender preference has been reported.

Main Characteristics

Four main characteristics are commonly seen in individuals with LDS. These features are not usually seen all together in other connective tissue disorders as major characteristics. These symptoms
include:

• Arterial tortuosity, most often occurring in the vessels of the neck
• Ocular hypertelorism
• Bifid uvula or cleft palate
• Dilatation or dissection of the aorta. Aortic root dilation is present in 95% of patients.

Main Medical Characteristics

Cardiovascular. The major sources of morbidity and early mortality in LDS are dilatation of the aorta at the level of the sinuses of Valsalva, a predisposition for aortic dissection and rupture, mitral valveprolapse . (MVP) with or without regurgitation, and enlargement of the proximal pulmonary artery. The arterial involvement is widespread and arterial tortuosity is present in most individuals.

Aortic dissection has been observed in early childhood (age 6 months) and/or at aortic dimensionsthat do not confer risk in other connective tissue disorders such as Marfan syndrome. Arterial tortuosity can be generalized but most commonly involves the head and neck vessels. Arterial aneurysms have been observed in almost all side branches of the aorta including (but not limited to) the subclavian, renal, superior mesenteric, hepatic, and coronary arteries. Other recurrent findings include PDA, ASD and bicuspid aortic valve.

Skeletal:

The skeletal findings are characterized by Marfan syndrome -like skeletal features and joint laxity or contractures:

• Skeletal overgrowth in LDS is less pronounced than in Marfan syndrome and usually affects the digits more prominently than the long bones.
• Arachnodactyly is present in some, but true dolichostenomelia (leading to an increase in the arm span-to-height ratio and a decrease in the upper-to-lower segment ratio) is less common in LDS than in Marfan syndrome.
• Combined thumb and wrist signs were present in one-third of individuals with LDS.
• Overgrowth of the ribs can push the sternum in (pectus excavatum) or out (pectus carinatum).

Joint hypermobility is common and can include congenital hip dislocation and recurrent joint subluxations.

Spine anomalies, including congenital malformations of the cervical vertebrae and cervical spine
instability, are common.

Craniofacial. In its most typical presentation, LDS presents with ocular hypertelorism and craniosynostosis (most commonly involving sagittal suture resulting in dolichocephaly).

Bifid uvula/cleft palate. Other characteristics include malar flattening and retrognathia.

Eye. Myopia is less frequent and less severe than that seen in Marfan syndrome. Retinal detachment has been reported rarely. Other common ocular features include strabismus and blue sclera. Ectopia lentis is not observed.

Skin. The skin findings, similar to those seen in vascular Ehlers-Danlos syndrome, include velvety, thin, translucent skin with visible veins on the chest wall, easy bruising (other than on the lower legs), and slower scar formation and dystrophic scarring.

Other. Life-threatening manifestations include spontaneous rupture of the spleen and bowel.

Pregnancy. Complications include aortic dissection/rupture or uterine rupture during pregnancy and delivery, or aortic dissection/rupture in the immediate postpartum period.

Natural History

The natural history of LDS is characterized by aggressive arterial aneurysms (mean age at death 26.1 years) and high incidence of pregnancy-related complications including death and uterine rupture.

Management

Evaluations Following Initial Diagnosis

To establish the extent of disease in an individual diagnosed with LDS, the following evaluations are recommended:

• Echocardiography. Aortic root measurements must be interpreted based on consideration ofnormal values for age and body size

• MRA or CT scan with 3D reconstruction from head to pelvis to identify arterial aneurysms and arterial tortuosity throughout the arterial tree

• Radiographs to detect skeletal manifestations that may require attention by an orthopaedist (e.g., severe scoliosis, cervical spine instability)

• Craniofacial examination for evidence of cleft palate and craniosynostosis

• Eye examination: slit-lamp examination for exclusion of lens subluxation; careful refraction and visual correction; specific assessment for retinal detachment and blue sclera.

Treatment

Aortic dissection occurs at smaller aortic diameters than observed in Marfan syndrome.Vascular disease is not limited to the aortic root.

• Beta-adrenergic blockers are used to reduce hemodynamic stress

• Aneurysms are amenable to early and aggressive surgical intervention. Many individuals can
receive a valve-sparing procedure that precludes the need for chronic anticoagulation.

• For young children, surgical repair of the ascending aorta should be considered once the
maximal dimension exceeds the 99th percentile and the aortic annulus exceeds 1.8 cm, allowing the
placement of a graft of sufficient size to accommodate growth.

• For adolescents and adults, surgical repair of the ascending aorta should be considered once
the maximal dimension approaches 4.0 cm.

Therapies Under Investigation

Experimental evidence suggests that many manifestations of LDS relate to excess activation of and signaling by the growth factor TGF.

Animal trials are underway to determine whether TGF antagonizing agents, such as angiotensin II receptor type 1 blockers, can slow or prevent manifestations of LDS.

References

1. Loeys BL, Dietz HC. Loeys-Dietz Syndrome. 2008 Feb 28 [Updated 2008 Apr 29]. In: Pagon RA, Bird TD, Dolan CR, et al., editors. GeneReviews™ [Internet]. Seattle (WA): University of Washington, Seattle; 1993-.Available from: http://www.ncbi.nlm.nih.gov/books/NBK1133/

2. Arbustini E, Marziliano N, Magrassi L. Aneurysm syndromes and TGFbeta receptor mutations. *N Engl J Med.* 2006; 355: 2155.

3. Wessels MW, Catsman-Berrevoets CE, Mancini GM, Breuning MH, Hoogeboom JJ, Stroink H, Frohn-Mulder I, Coucke PJ, Paepe AD, Niermeijer MF, Willems PJ. Three new families with arterial tortuosity syndrome. *Am J Med Genet A.* 2004; 131: 134–43.

4. Yetman AT, Beroukhim RS, Ivy DD, Manchester D. Importance of the clinical recognition of Loeys-Dietz syndrome in the neonatal period. *Pediatrics.* 2007; 119: e1199–202.

5. Roman MJ, Devereux RB, Kramer-Fox R, O'Loughlin J. Two-dimensional echocardiographic aortic root dimensions in normal children and adults. *Am J Cardiol.* 1989; 64: 507–12.

6. Pannu H, Fadulu VT, Chang J, Lafont A, Hasham SN, Sparks E, Giampietro PF, Zaleski C,Estrera AL, Safi HJ, Shete S, Willing MC, Raman CS, Milewicz DM. Mutations in transforming growth
factor-beta receptor type II cause familial thoracic aortic aneurysms and dissections. *Circulation.* 2005; 112: 513–20.

7. Loeys BL, Schwarze U, Holm T, Callewaert BL, Thomas GH, Pannu H, De Backer JF, Oswald GL, Symoens S, Manouvrier S, Roberts AE, Faravelli F, Greco MA, Pyeritz RE, Milewicz DM, Coucke PJ, Cameron DE, Braverman AC, Byers PH, De Paepe AM, Dietz HC. Aneurysm syndromes caused by mutations in the TGF-beta receptor. *N Engl J Med.* 2006; 355: 788–98.

8. Loeys BL, Chen J, Neptune ER, Judge DP, Podowski M, Holm T, Meyers J, Leitch CC, Katsanis N, Sharifi N, Xu FL, Myers LA, Spevak PJ, Cameron DE, De Backer J, Hellemans J, Chen Y, Davis EC, Webb CL, Kress W, Coucke P, Rifkin DB, De Paepe AM, Dietz HC. A syndrome of altered cardiovascular, craniofacial, neurocognitive and skeletal development caused by mutations in TGFBR1 or TGFBR2. *Nat Genet.* 2005; 37: 275–81.